

# Herpetic Keratitis The Dilemma

Nancy M. Lotfy, MD.

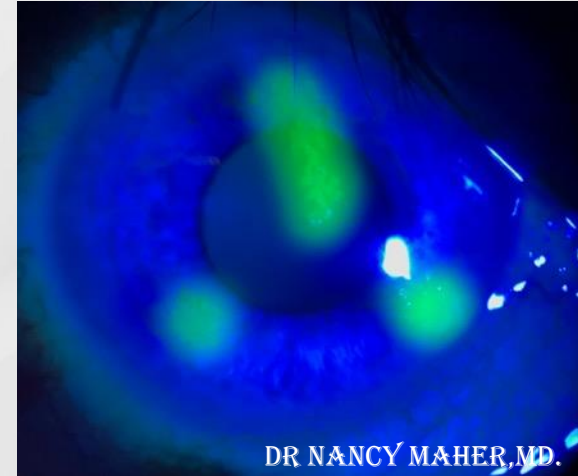
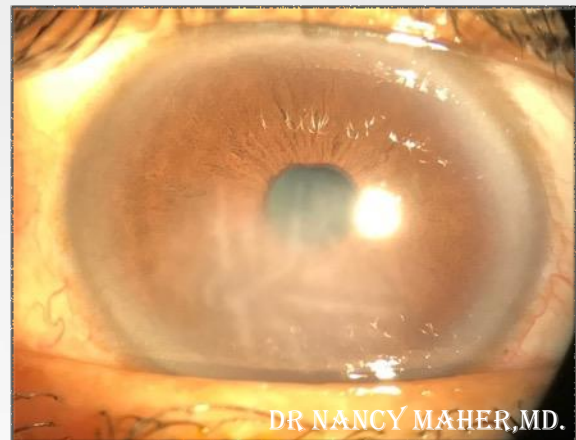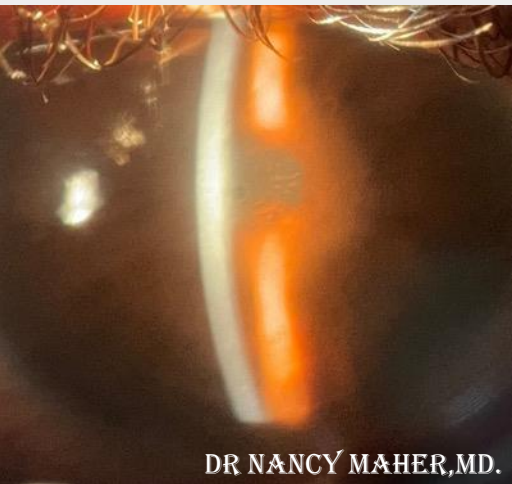
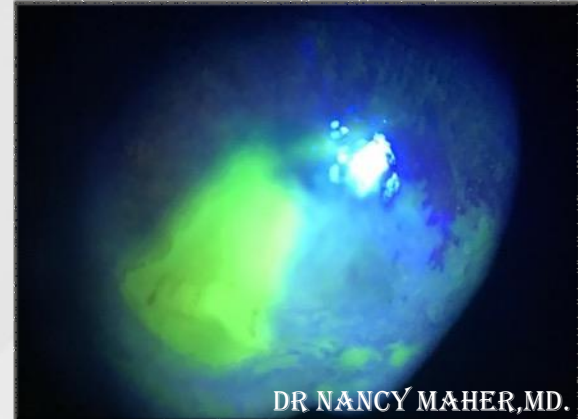
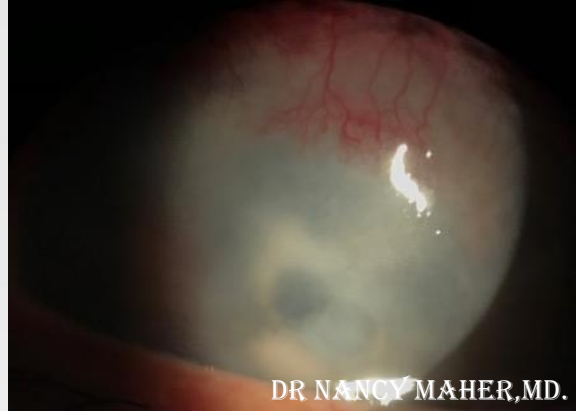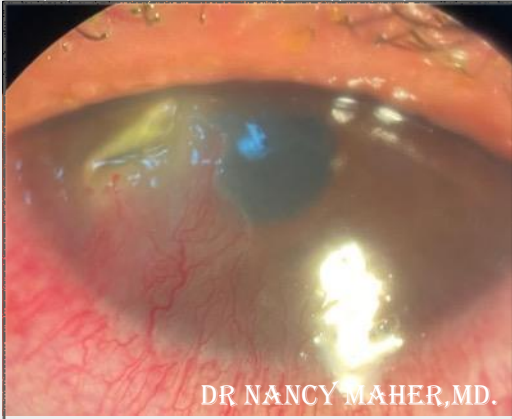Associate Professor of Ophthalmology, Cairo University, Egypt.

# Epidemiology

- HSV is the leading infectious cause of corneal blindness among developed countries.
- Herpetic keratitis is endemic throughout the world.
- 90% of the world's population is infected with HSV-1 by the age of 60.



# Clinical presentations



10<sup>TH</sup> EVOLVING PRACTICE OF OPHTHALMOLOGY  
MIDDLE EAST CONFERENCE

# Case 1

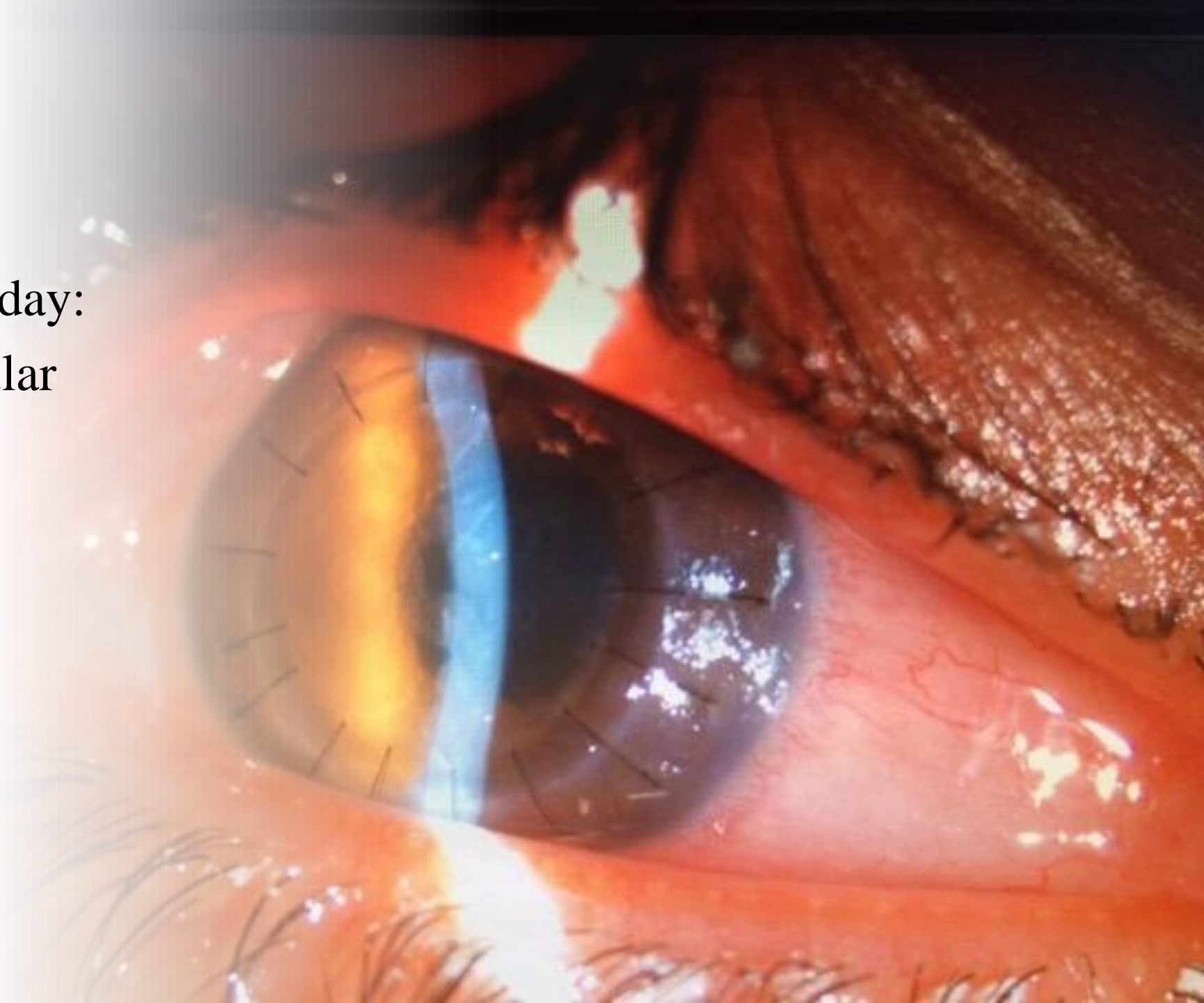- 22 years old male patient.
- Bilateral corneal dystrophy.
- BCVA 20/60
- RT PKP
- 3rd post-operative day the graft was clear with healed ED.

# Case 1

➤ 5th post-operative day:

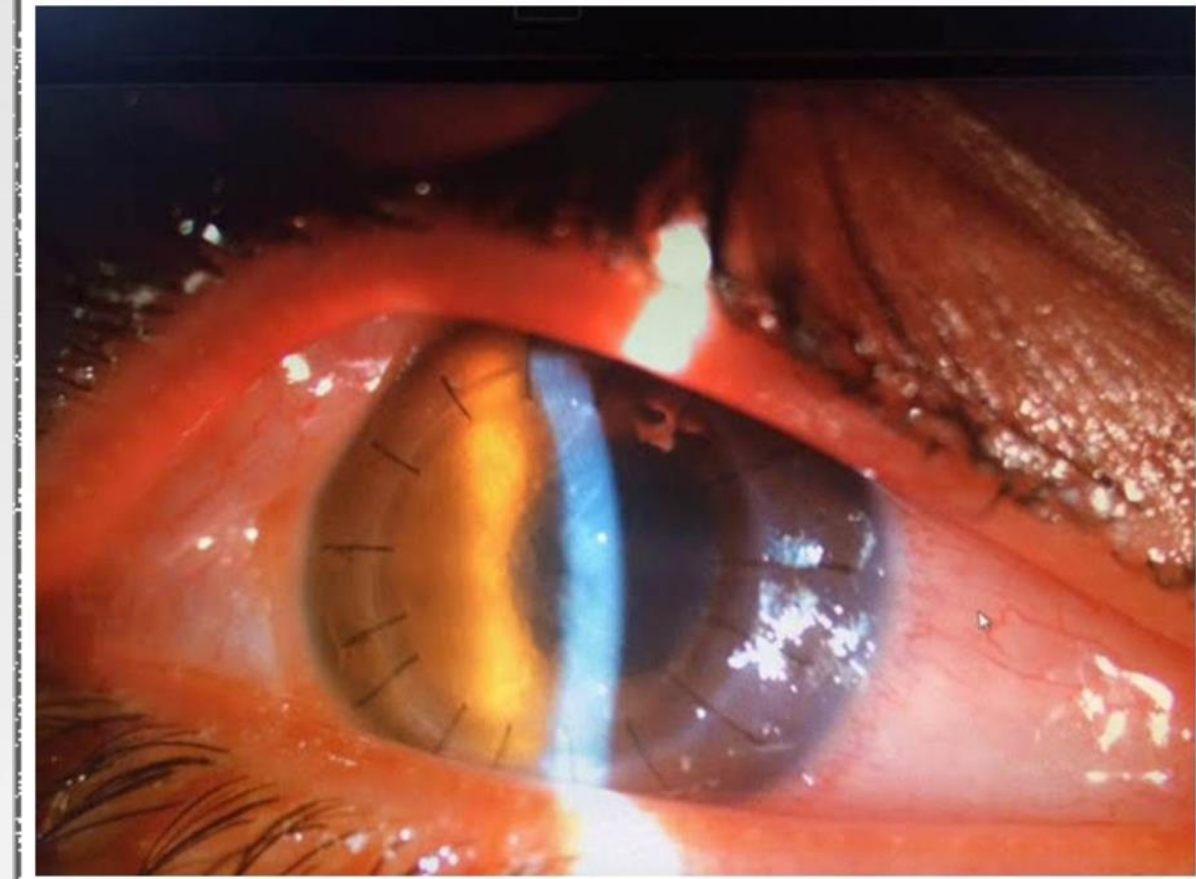- Endothelial nummular deposits.
- BCVA 20/200
- IOP 18 mmhg

Microbial keratitis  
VS  
Graft rejection.



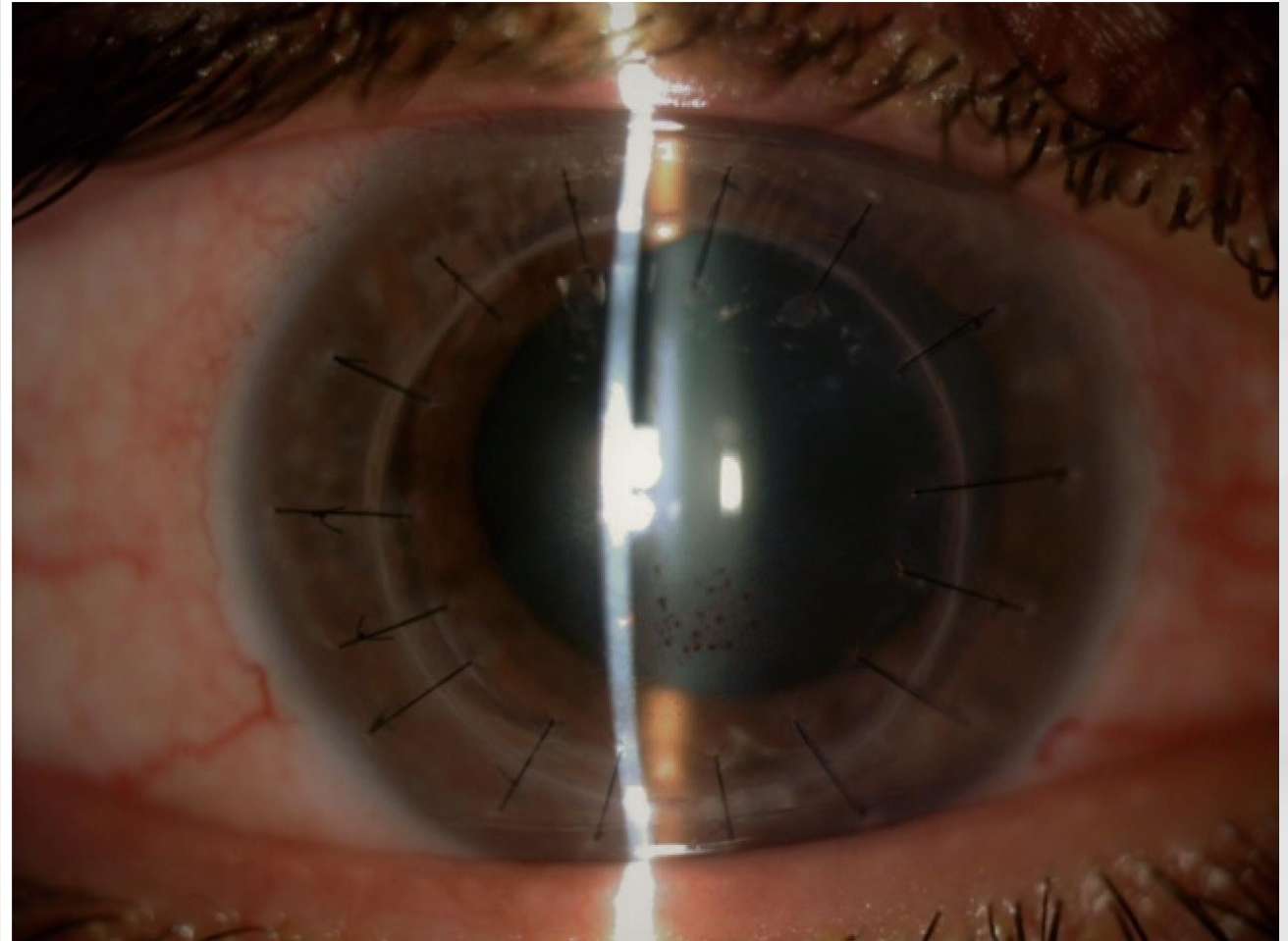
# Case 1

- 9th post-operative day
- IOP 45 mmhg
- -ve microbial results
- Viral keratitis suspected



# Case 1

-ve PCR



# Case 1



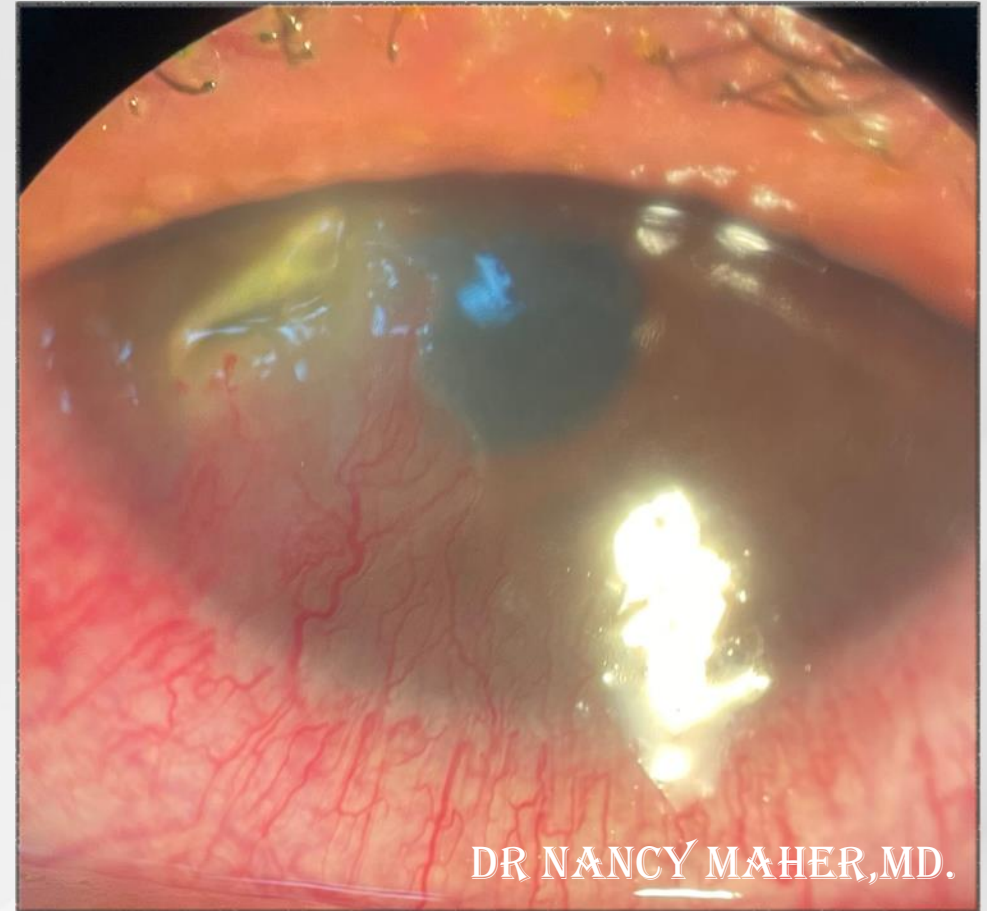
## THE TAKE-HOME MESSAGE

- Herpetic keratitis should be considered in all cases of unexplained post PKP inflammation or infection.
- Negative PCR does not rule out herpetic keratitis.



# Case 2

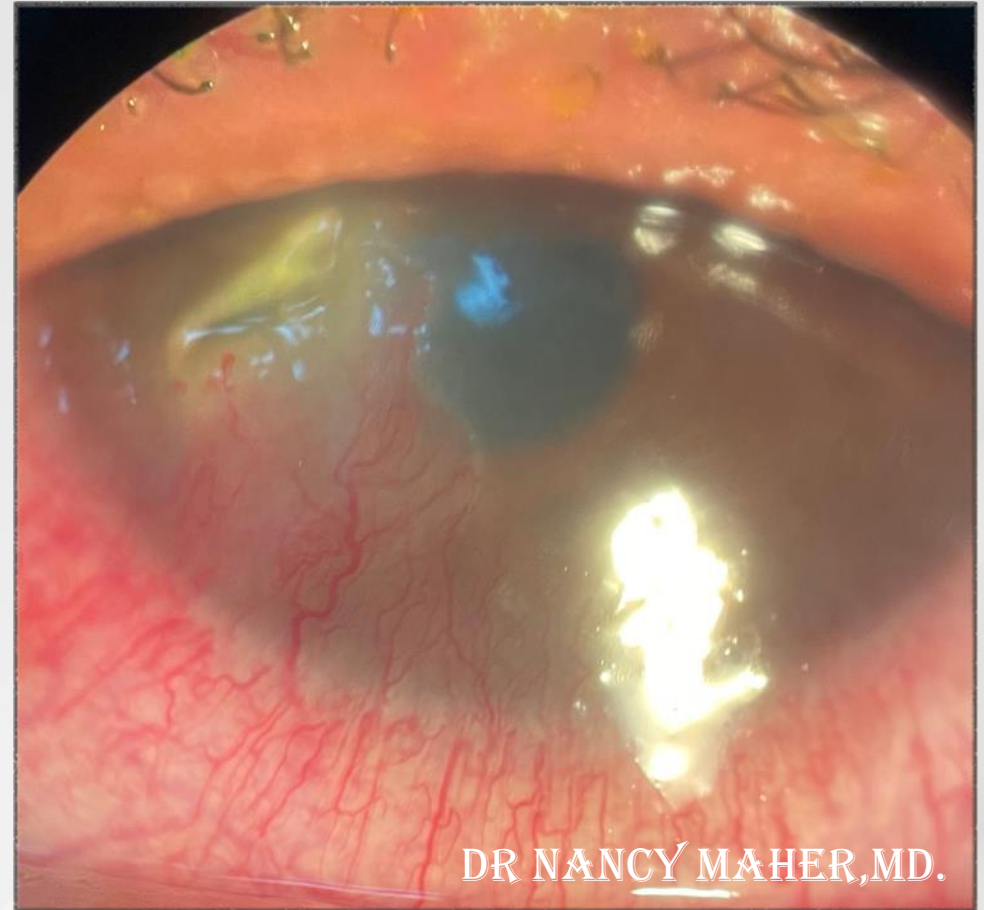- 35 years old female patient.
- C/O LT eye redness and pain.
- BCVA 20/70
- IOP 14
- Clear vitreous.



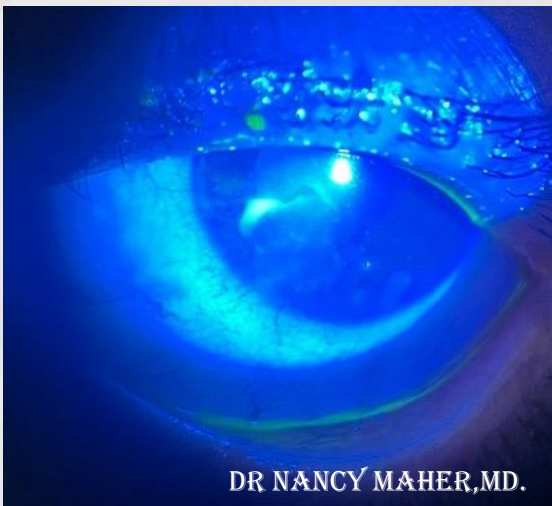
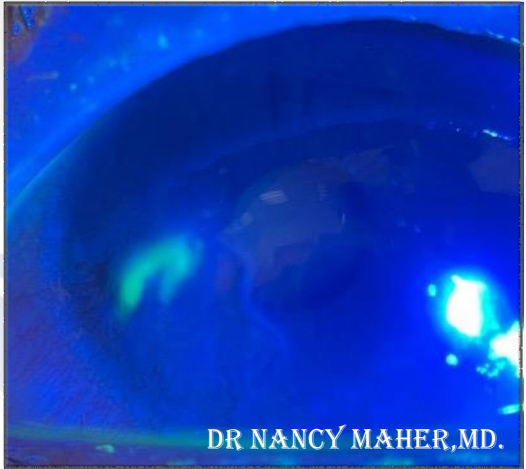
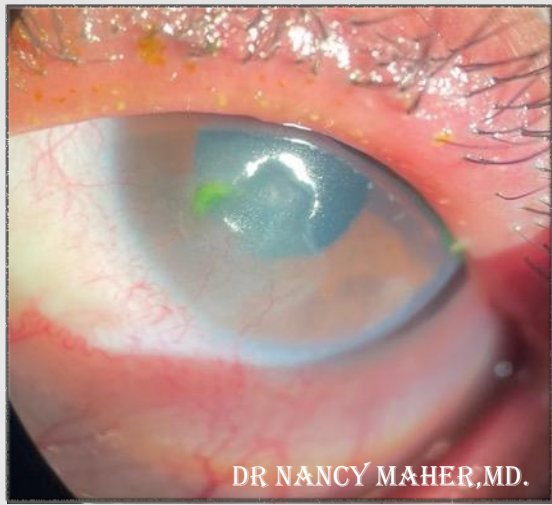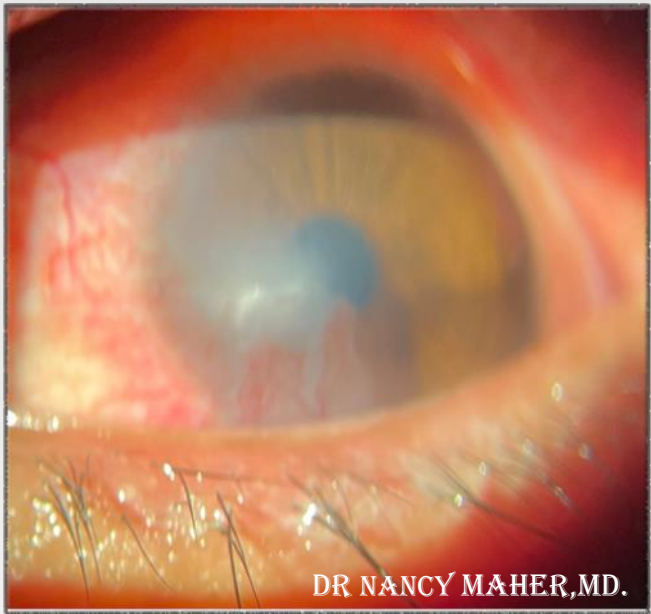
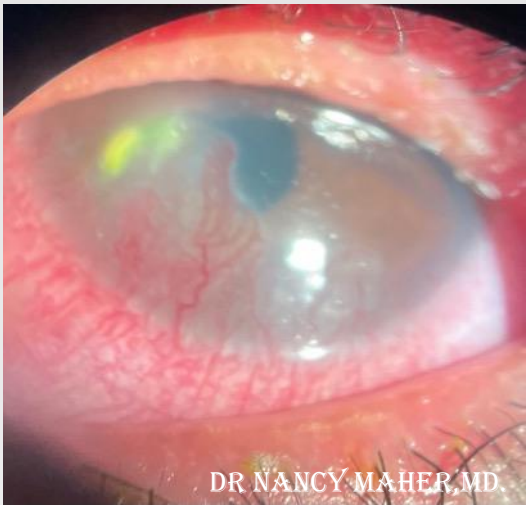DR NANCY MAHER, MD.

# Case 2

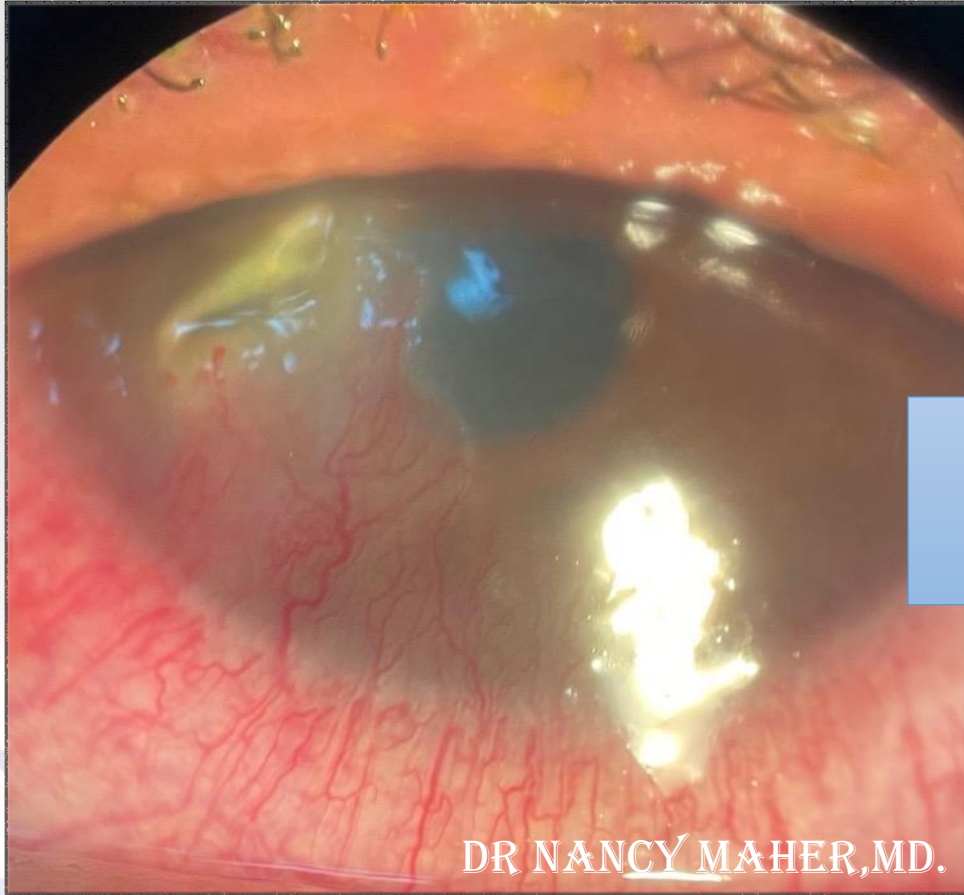
- ❑ HSV stromal keratitis
- ❑ PUK



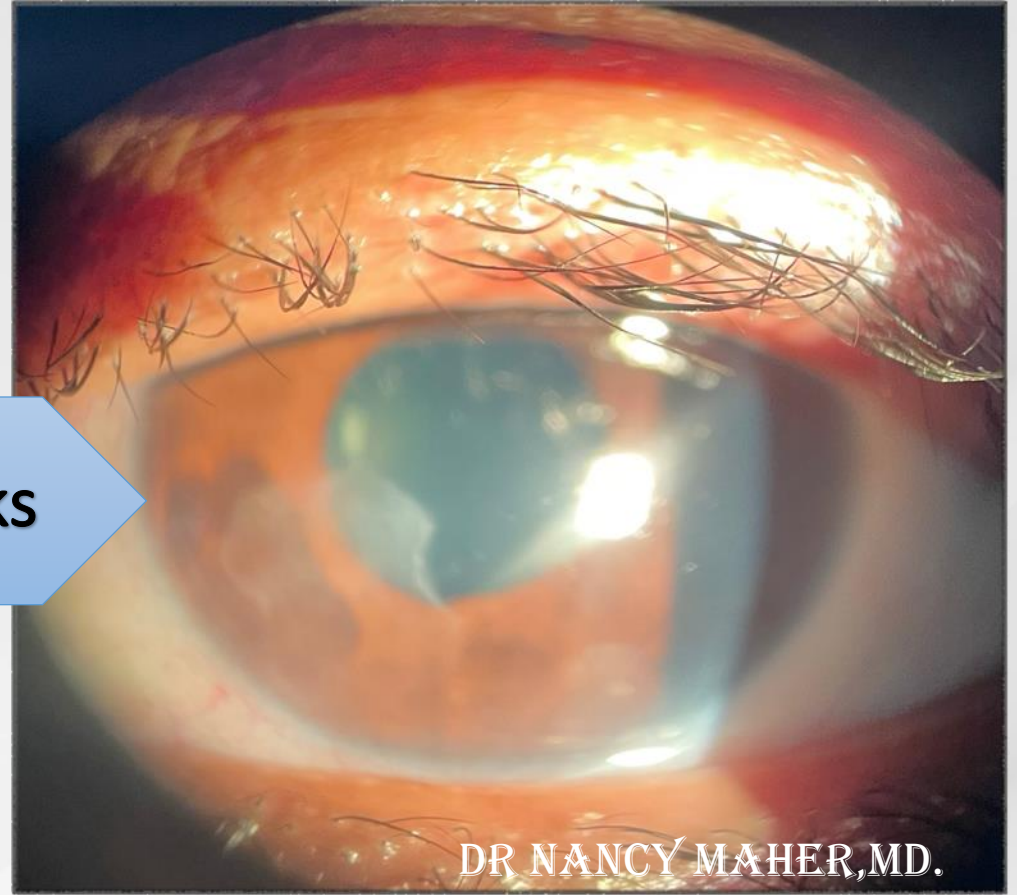
# Case 2



# Case 2

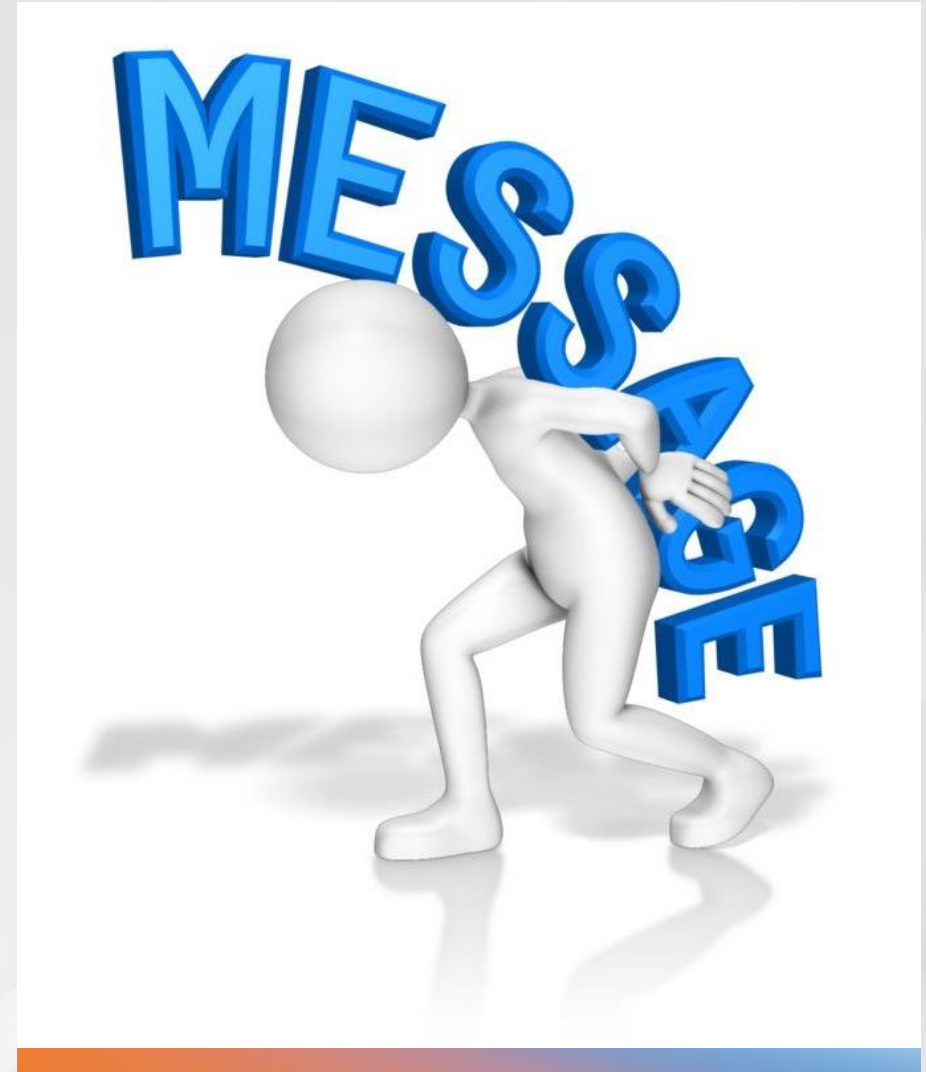


5 weeks

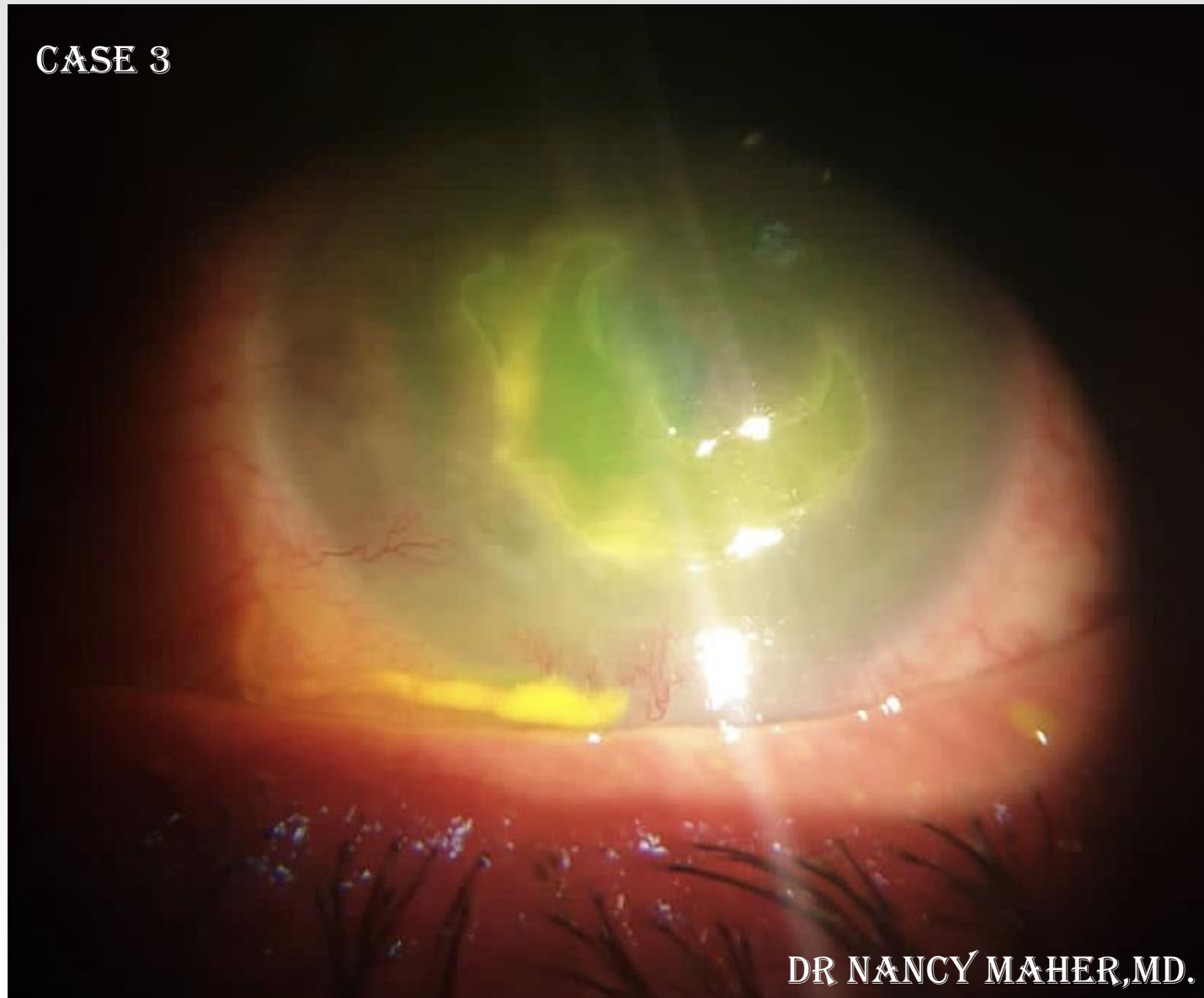


## Case 2

- Herpetic keratitis should be considered in all cases of PUK.
- Negative PCR does not rule out herpetic keratitis.



**CASE 3**

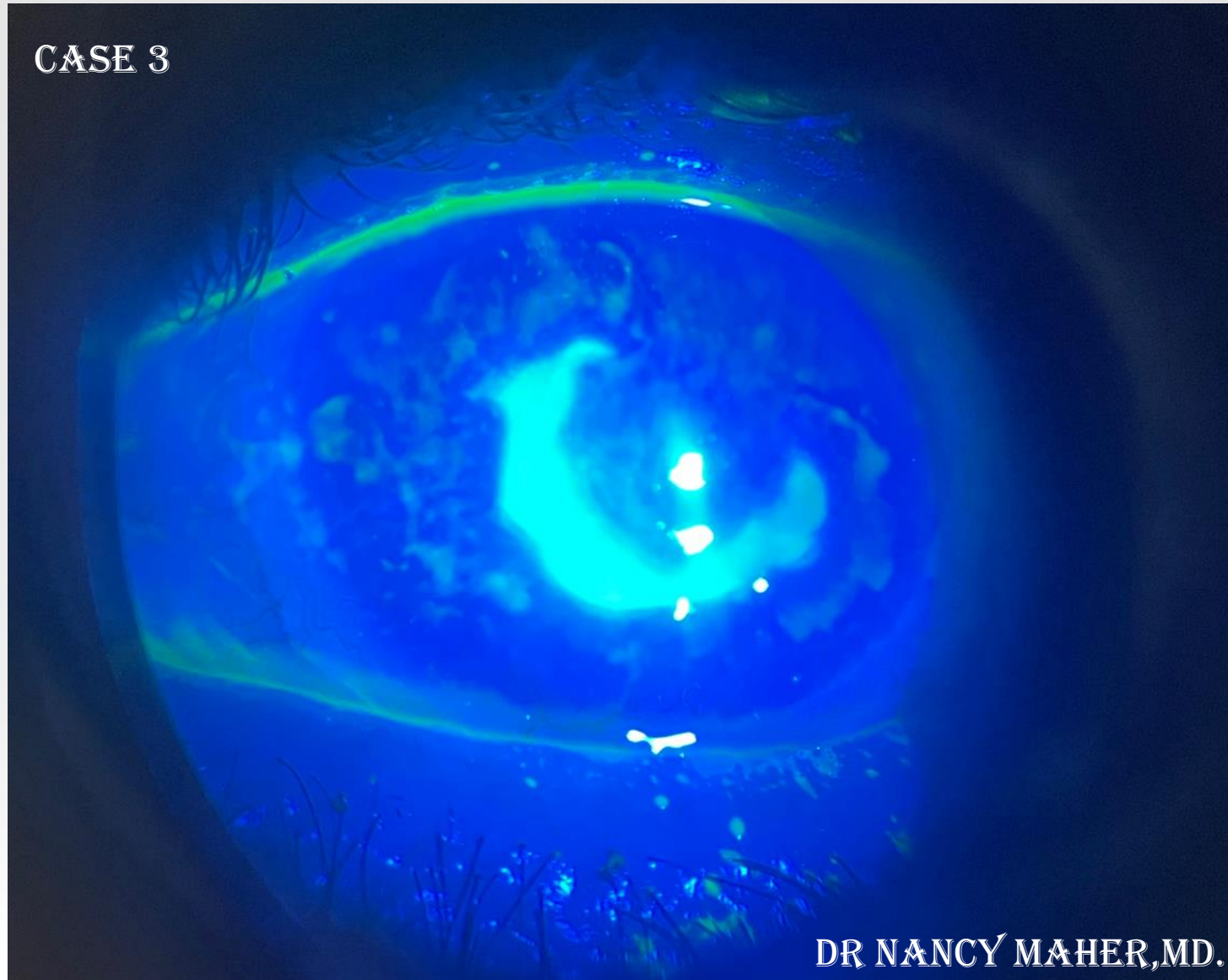


**DR NANCY MAHER, MD.**

**10<sup>TH</sup> EVOLVING PRACTICE OF OPHTHALMOLOGY  
MIDDLE EAST CONFERENCE**



CASE 3

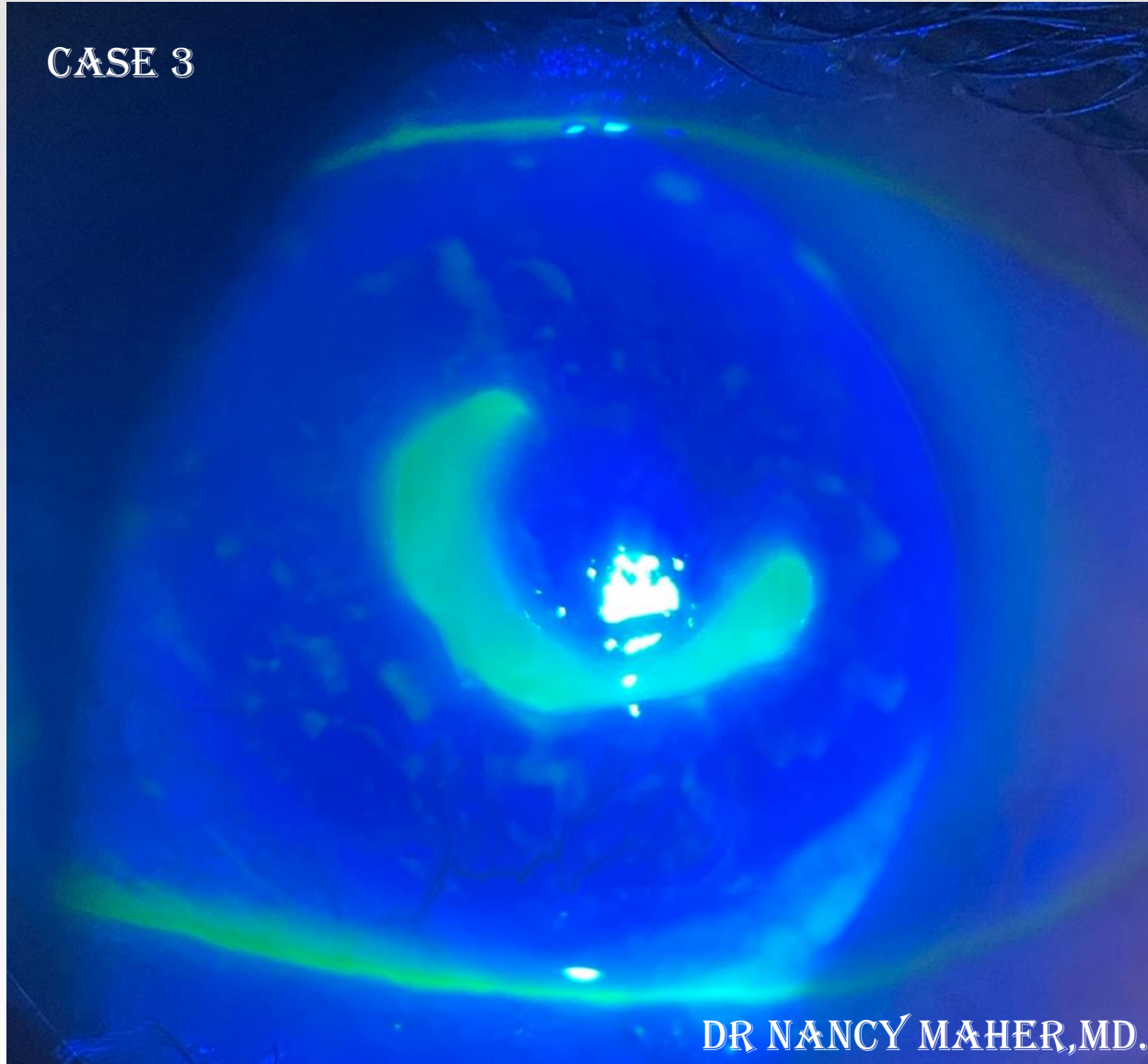


DR NANCY MAHER, MD.

10<sup>TH</sup> EVOLVING PRACTICE OF OPHTHALMOLOGY  
MIDDLE EAST CONFERENCE



CASE 3



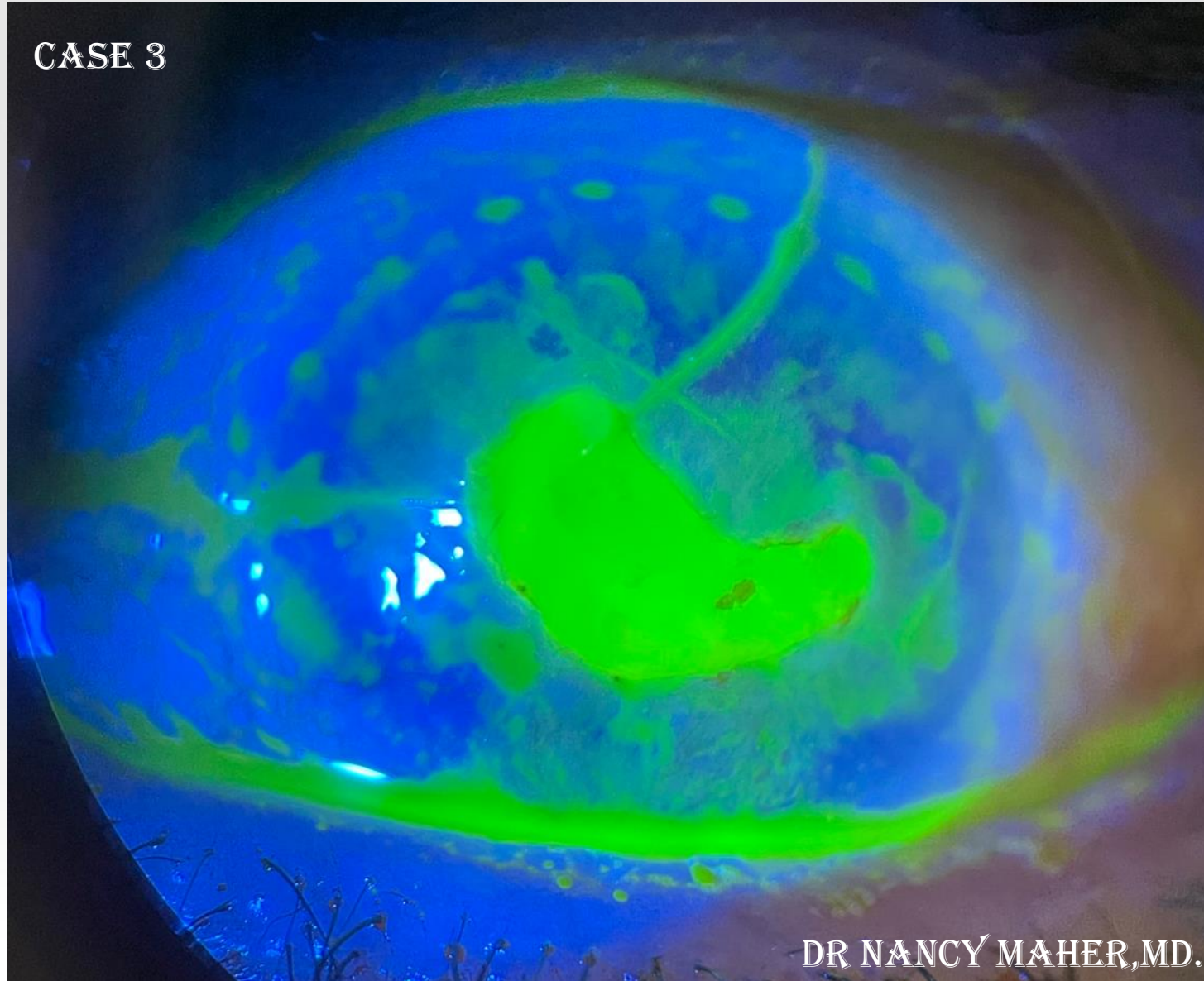
DR NANCY MAHER, MD.

10<sup>TH</sup> EVOLVING PRACTICE OF OPHTHALMOLOGY  
MIDDLE EAST CONFERENCE





CASE 3

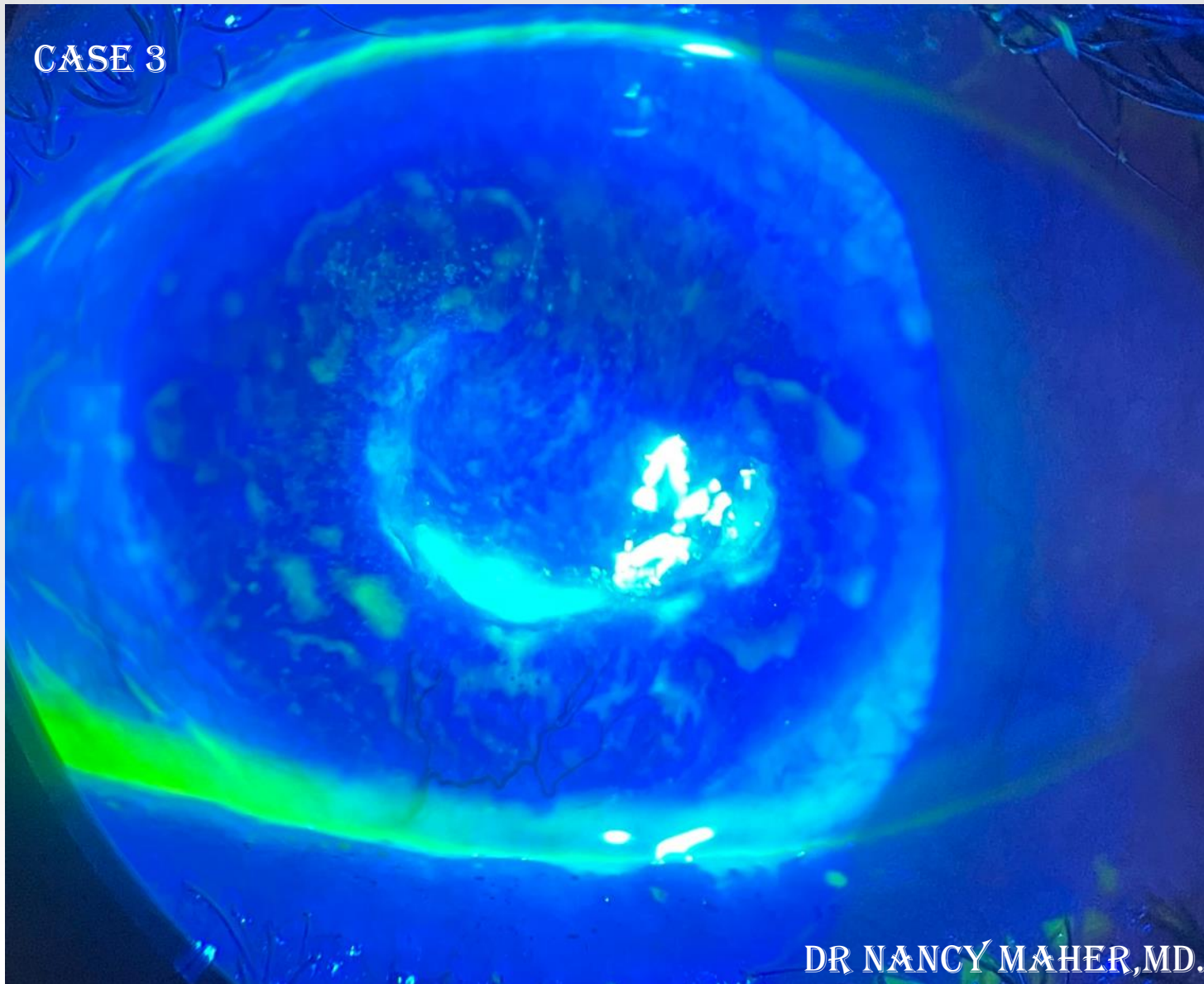


DR NANCY MAHER, MD.

10<sup>TH</sup> EVOLVING PRACTICE OF OPHTHALMOLOGY  
MIDDLE EAST CONFERENCE



CASE 3




DR NANCY MAHER, MD.

10<sup>TH</sup> EVOLVING PRACTICE OF OPHTHALMOLOGY  
MIDDLE EAST CONFERENCE



CASE 3

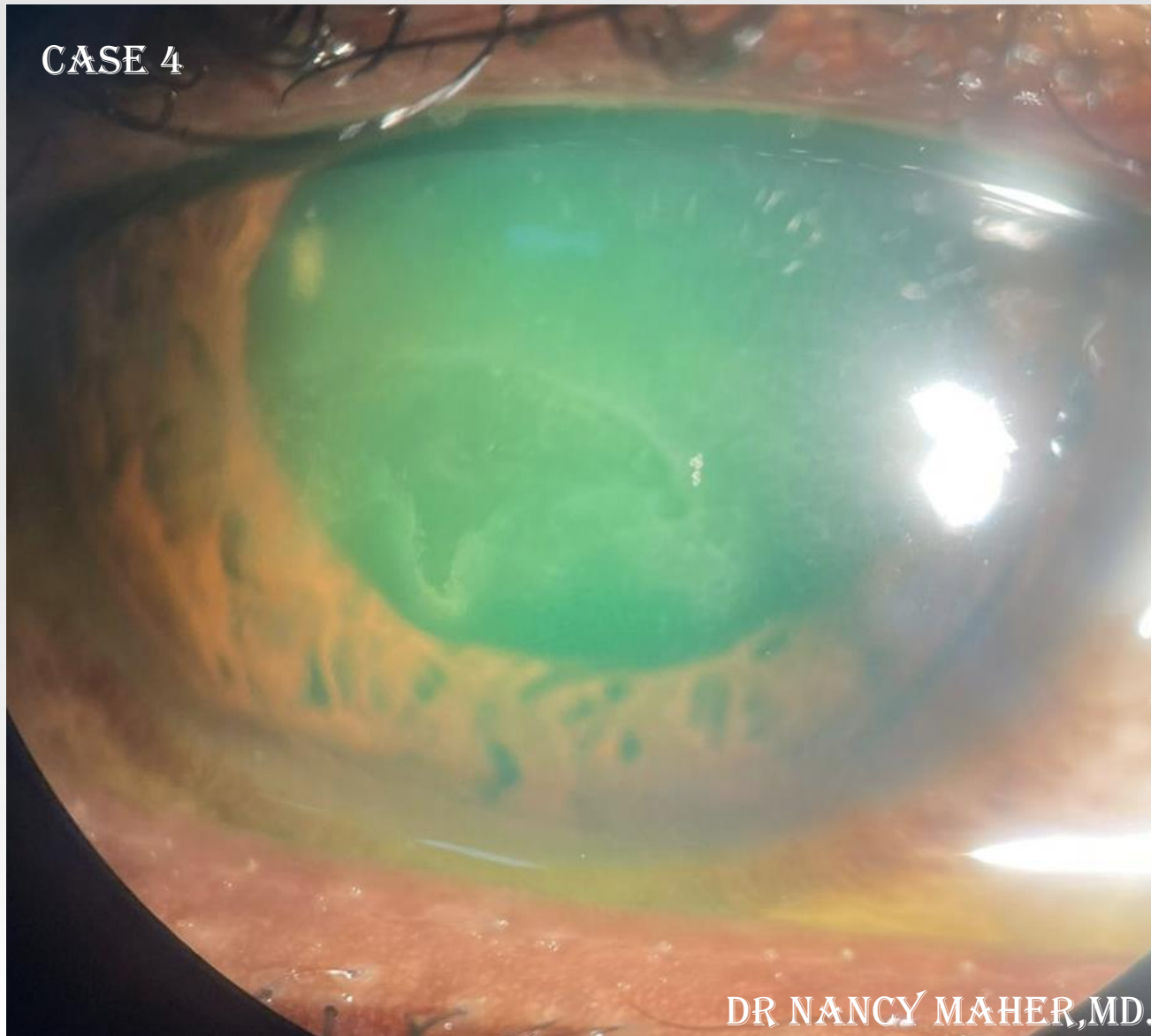

DR NANCY MAHER, MD.

10<sup>TH</sup> EVOLVING PRACTICE OF OPHTHALMOLOGY  
MIDDLE EAST CONFERENCE



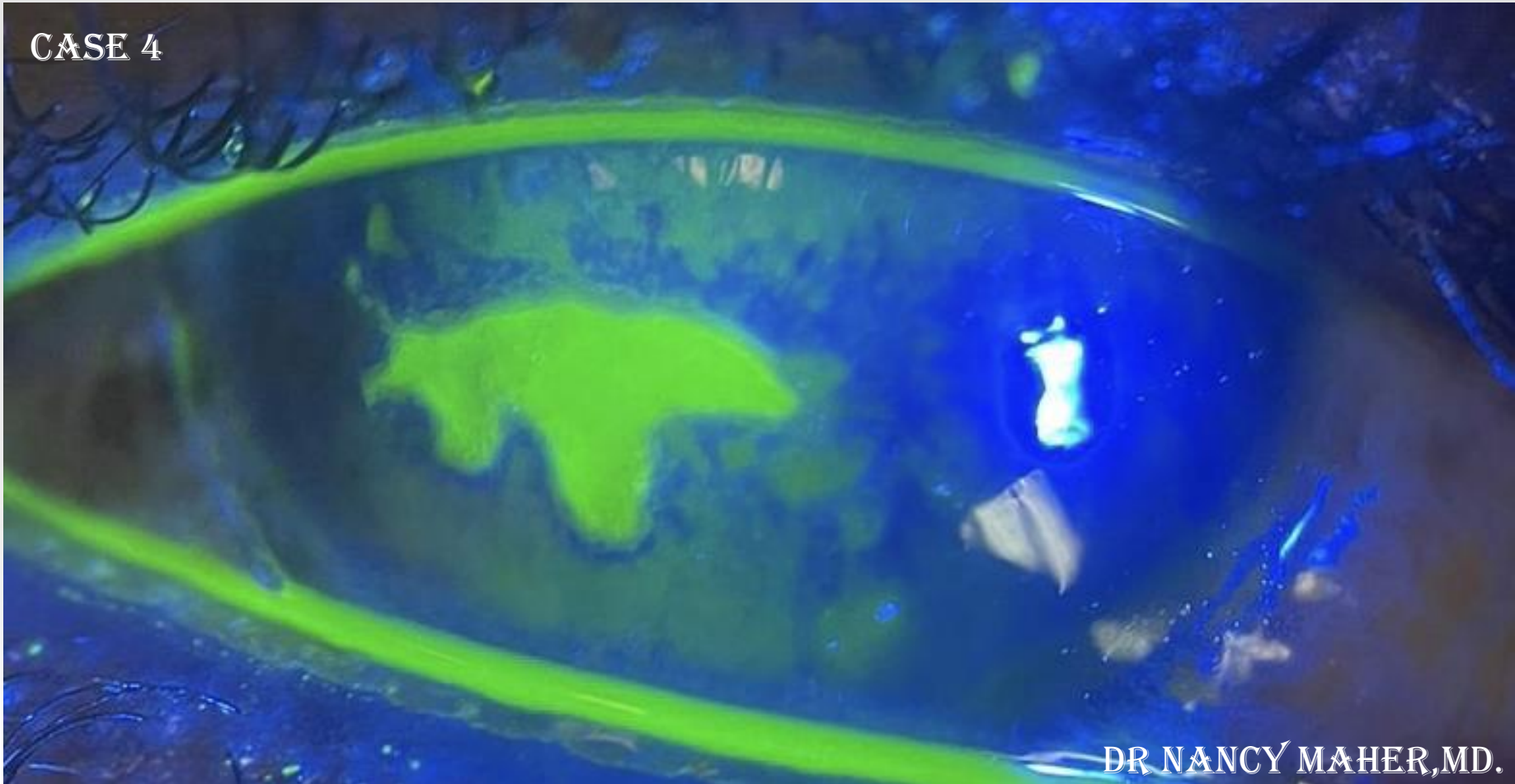
CASE 4



DR NANCY MAHER, MD.

10<sup>TH</sup> EVOLVING PRACTICE OF OPHTHALMOLOGY  
MIDDLE EAST CONFERENCE

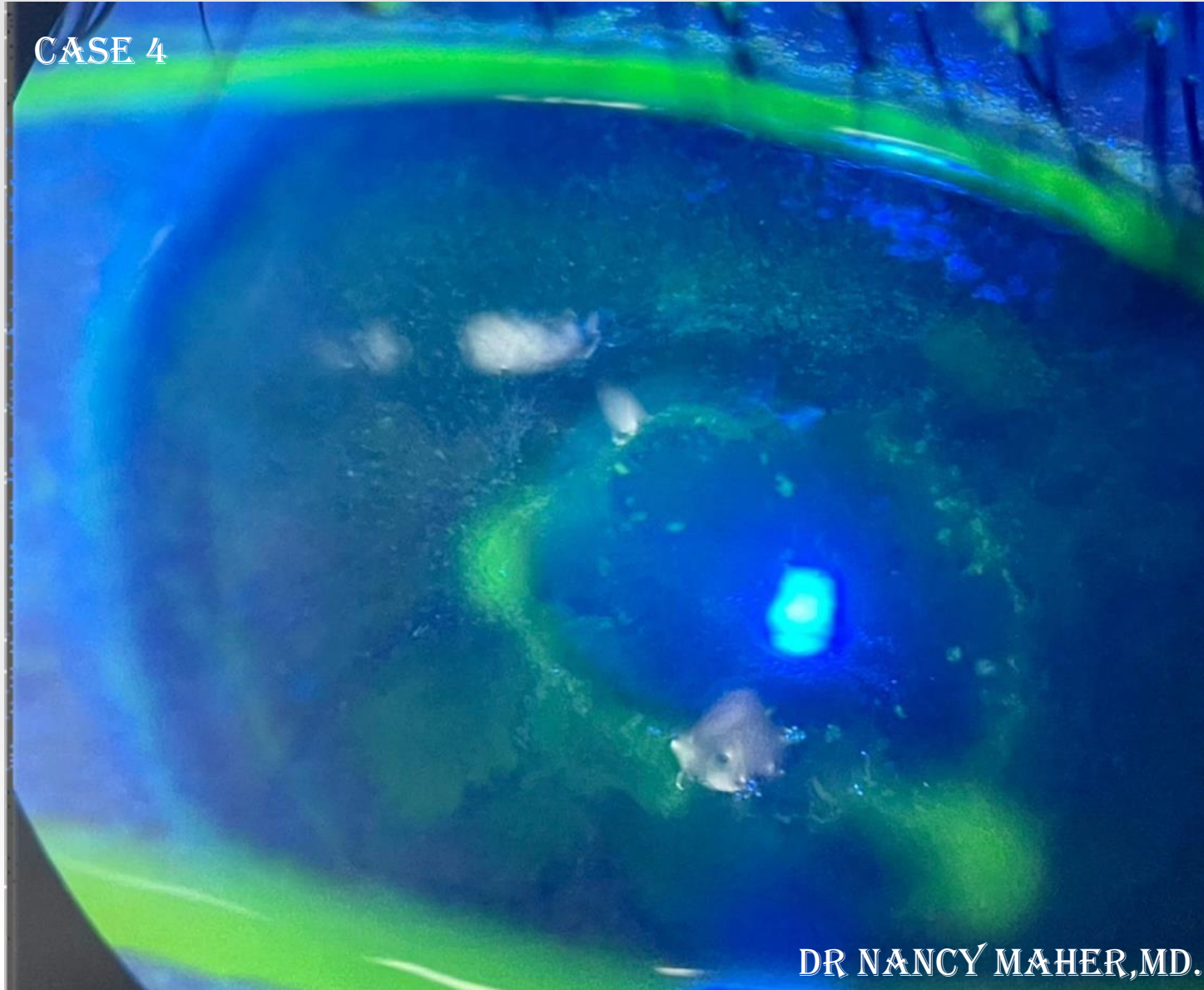




10<sup>TH</sup> EVOLVING PRACTICE OF OPHTHALMOLOGY  
MIDDLE EAST CONFERENCE



CASE 4

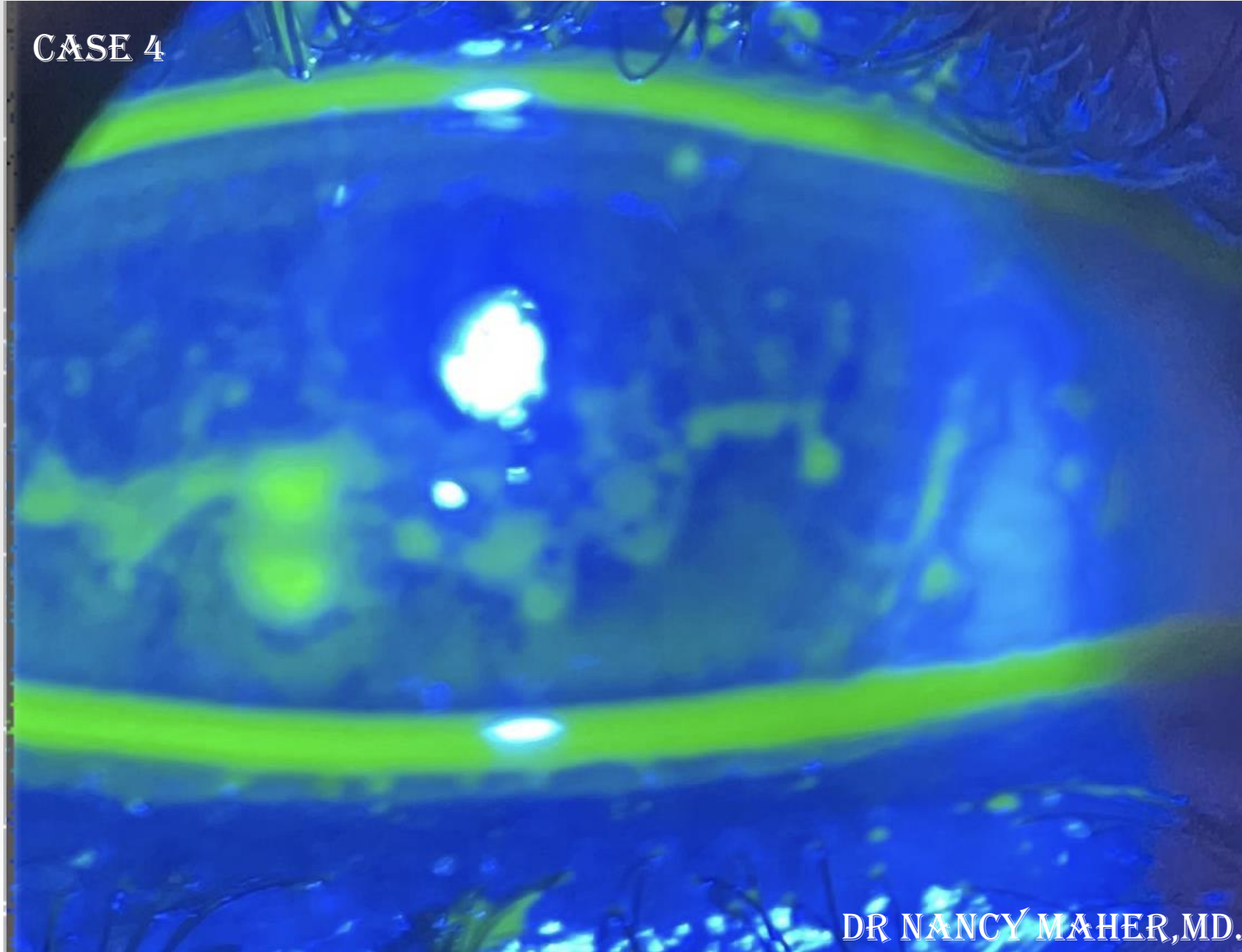


DR NANCY MAHER, MD.

10<sup>TH</sup> EVOLVING PRACTICE OF OPHTHALMOLOGY  
MIDDLE EAST CONFERENCE



CASE 4

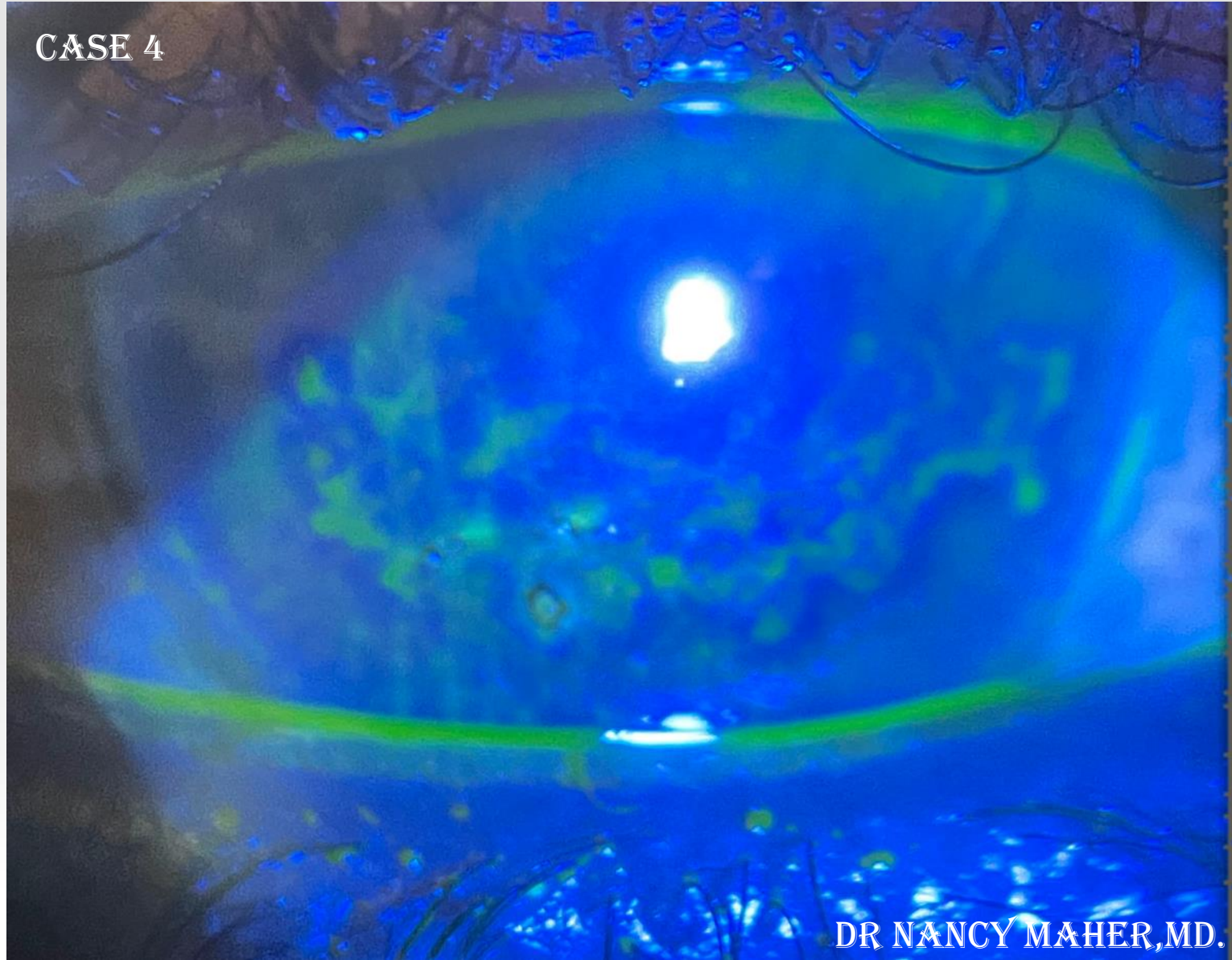

DR NANCY MAHER, MD.

10<sup>TH</sup> EVOLVING PRACTICE OF OPHTHALMOLOGY  
MIDDLE EAST CONFERENCE



CASE 4



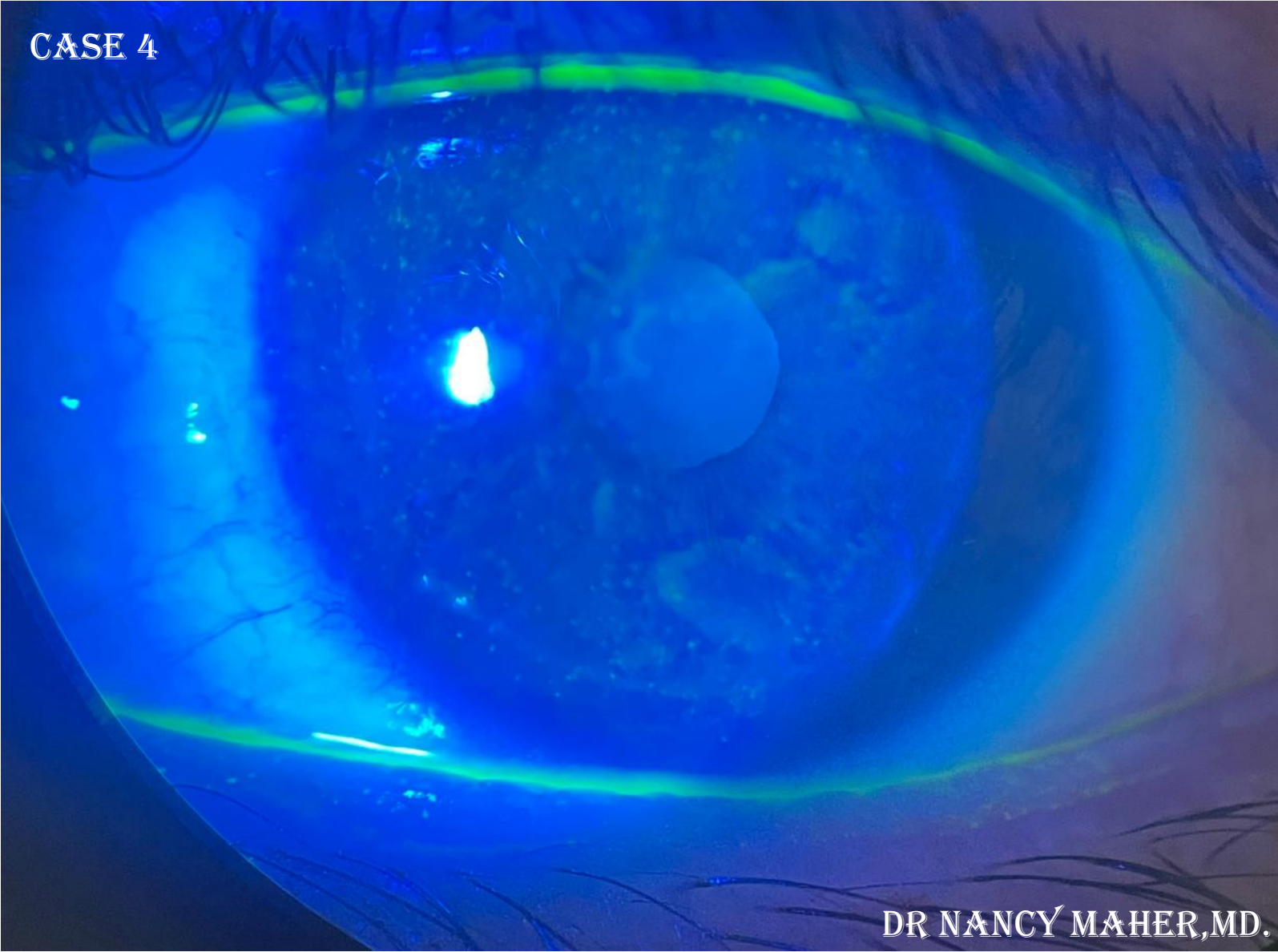
DR NANCY MAHER, MD.

10<sup>TH</sup> EVOLVING PRACTICE OF OPHTHALMOLOGY  
MIDDLE EAST CONFERENCE





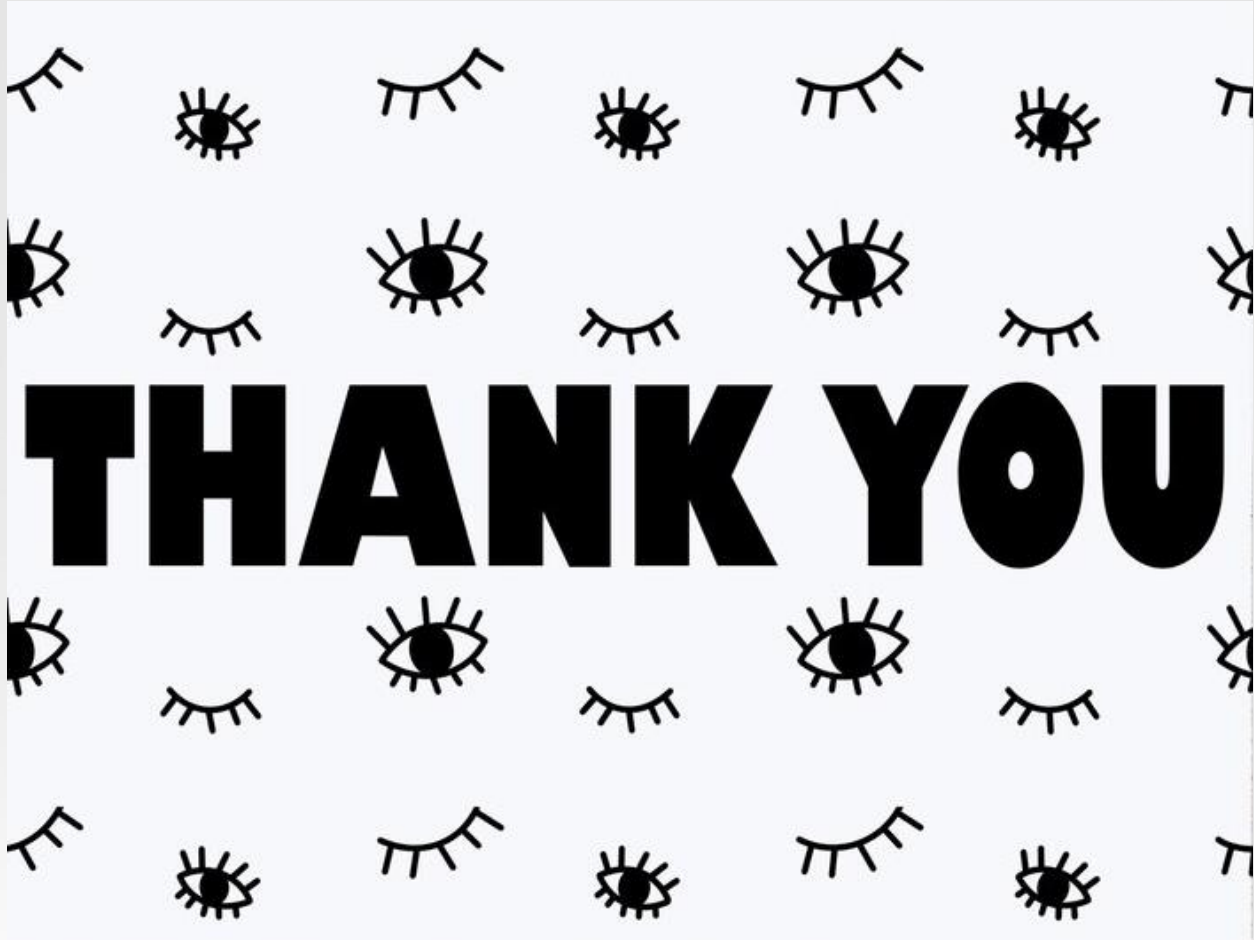CASE 4



DR NANCY MAHER, MD.

10<sup>TH</sup> EVOLVING PRACTICE OF OPHTHALMOLOGY  
MIDDLE EAST CONFERENCE





10<sup>TH</sup> EVOLVING PRACTICE OF OPHTHALMOLOGY  
MIDDLE EAST CONFERENCE

