

# Pseudoexfoliation syndrome in cataract surgery a retrospective study of 39 cases

**S.Laababsi, M.Makmoul, M.R.Bentouhami, Y.Hidan, A.Mchachi, L.Benhmidoune, R.Rachid, M.Elbelhadji**

**Adult Ophthalmology Department**

**August 20 Hospital, Ibn Rochd University Hospital**

**Faculty of Medicine and Pharmacy of Casablanca, Hassan II University, Casablanca, Morocco**

No relevant conflicts of interest to declare



# Table of contents



- Introduction



- Materials and methods



- Results



- Discussion



- Conclusion



**Introduction**

Materials  
and Methods

Results

Discussion

Conclusion

# Introduction



## Introduction

## Materials and Methods

## Results

## Discussion

## Conclusion

- Pseudoexfoliation ou PXF : an age-related systemic disorder of unknown etiology
- the production and abnormal deposition of fibrillar material in the anterior segment
- Diagnosis is clinical, with a typical cocoon-like appearance of exfoliative material deposited on the lens capsule
- Prevalence increases with age
- PXE represents an obstacle for surgeons during cataract surgery because of increase the risk of intraoperative and postoperative complications due to weakness of the zonules and poor pupillary dilation.

**Introduction**

Materials and  
Methods

Results

Discussion

Conclusion

## Aim of the study

The clinical features of pseudoexfoliation syndrome (PES) in Moroccan patients with age-related cataract scheduled for surgery

The complications in cataract surgery

Eyes with  
pseudoexfoliation  
syndrome

Eyes without  
pseudoexfoliation  
syndrome

same  
period

same  
surgeons

Introduction

Materials and  
Methods

Results

Discussion

Conclusion

# Materials and Methods



Introduction

Materials  
and Methods

Results

Discussion

Conclusion

- **Study design** : A cross-sectional, comparative and multicenter study.
- **Study time period** : From January 2023 to June 2023.
- **Study locations** : The Ophthalmology Department of the Ibn Rochd University Hospital of Casablanca, Morocco.
- **Study population**: 39 eyes with pseudoexfoliation syndrom operated on for cataract.
- **Data collection** : Patient medical records and a pre-established evaluation sheet.
- **Data analysis** :
  - Programs** : Microsoft Excel™ 2019 and IBM SPSS 20.
  - Statistical significance** : A P value less than 0.05 with 95% confidence interval.





**Introduction**

**Materials  
and Methods**

**Results**

**Discussion**

**Conclusion**

# Results

**Introduction**

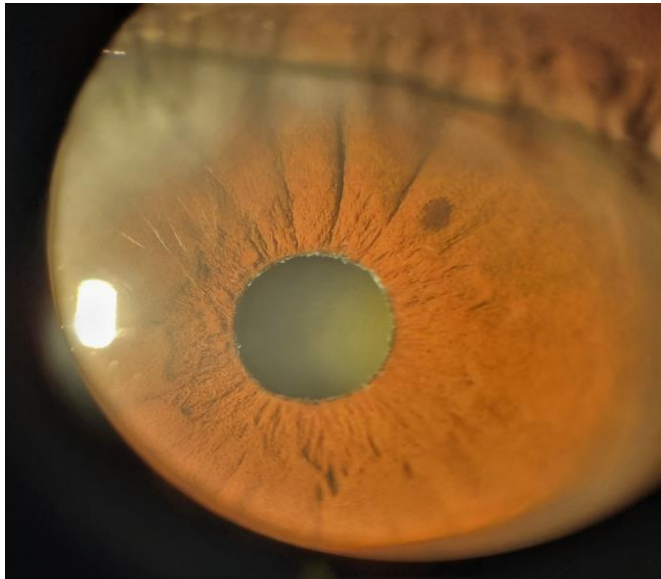**Materials and  
methods**

**Results**

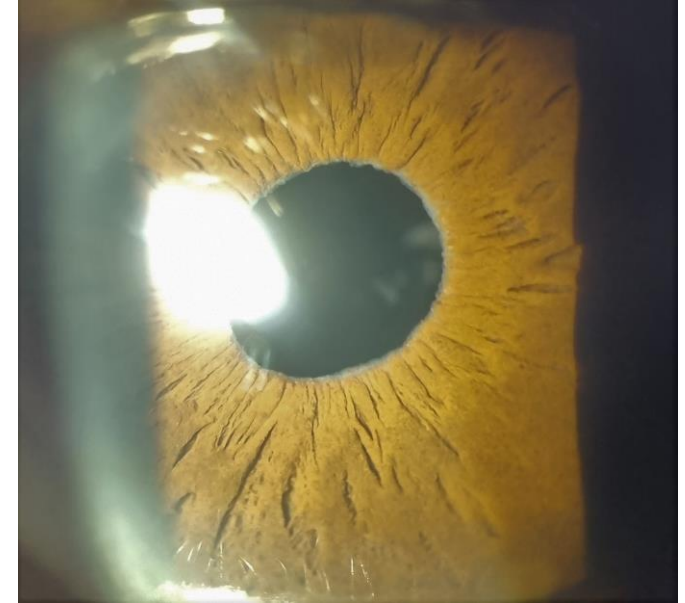
**Discussion**

**Conclusion**

**Descriptive study**



**A total of 78 patients**



**39 eyes with  
pseudoexfoliation**

**39 eyes without  
pseudoexfoliation**

## I. Study population characteristics :

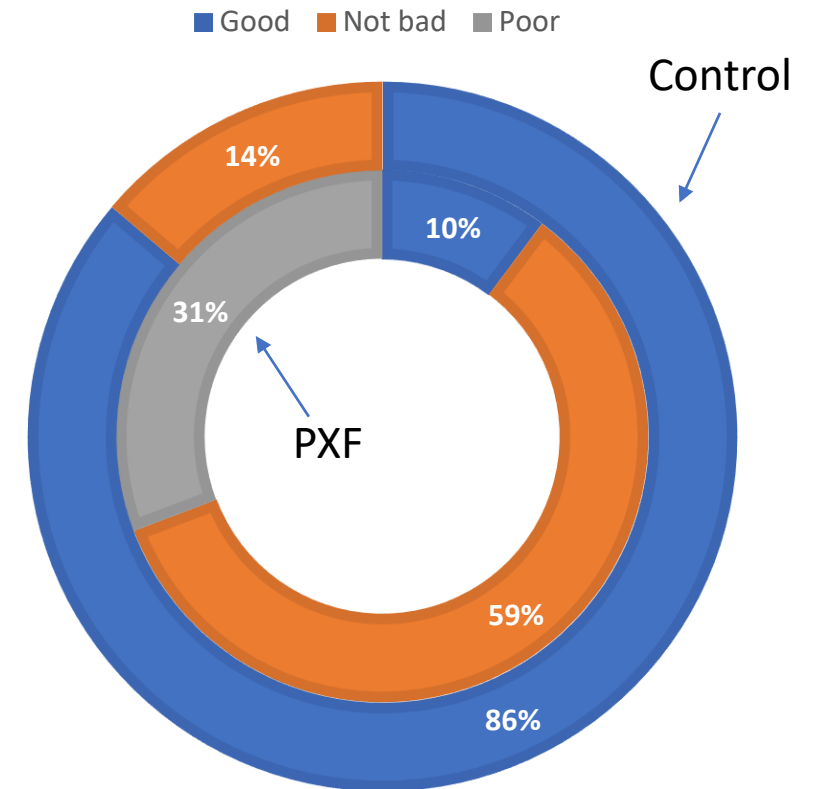
Age	PXF	Control
51-60	7 (17,9%)	12 (30,8%)
61-70	15 (38,5%)	15 (38,5%)
71-80	12 (30,8%)	11 (28,2%)
81 and above	5 (12,8)	1 (2,6%)

Age and number of eyes with and without pseudoexfoliation (PXF)

The age group between 61 and 70 years, was the most affected (38,5%) in both groups

## II. Clinical data

	PXF	Control
<b>Number of eyes</b>	39	39
<b>Unilaterality</b>	10 (25,6%)	-
<b>Bilaterality</b>	29 (74,4%)	-
<b>Poor dilaration</b>	12 (30,8%)	-
<b>Associated HTO</b>	2 (2,5%)	-
<b>Associated HTA</b>	10 ( 25,6%)	10 (25,6%)

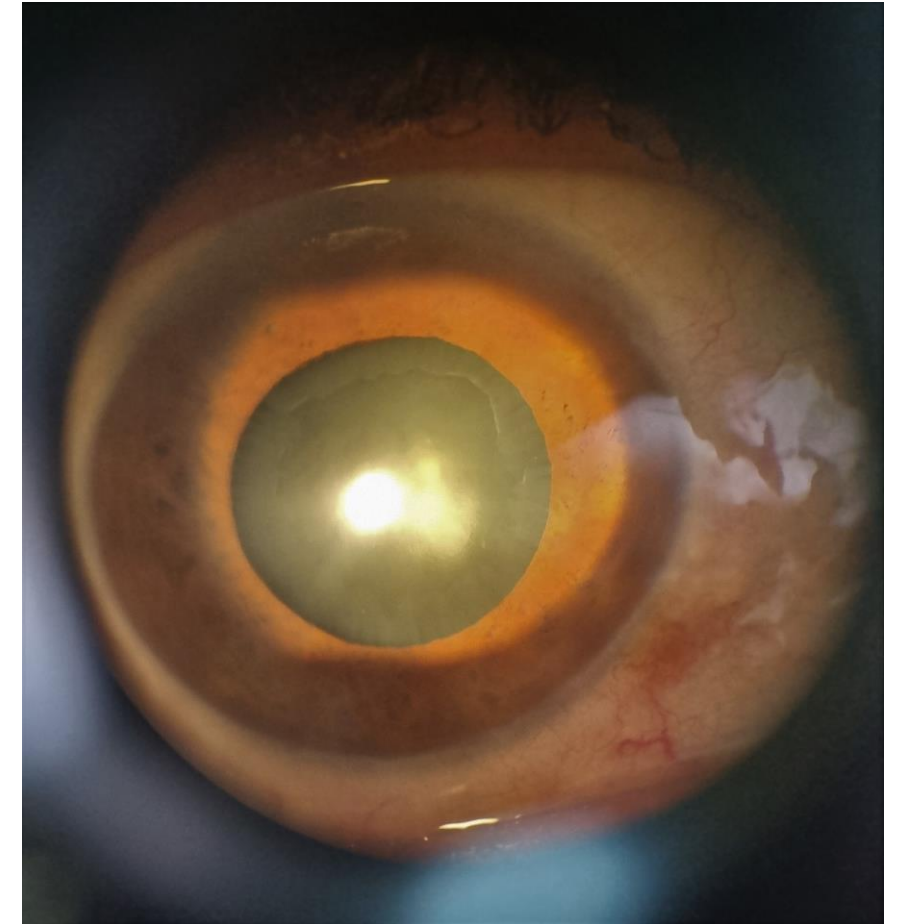


**Pupillary dilatation**

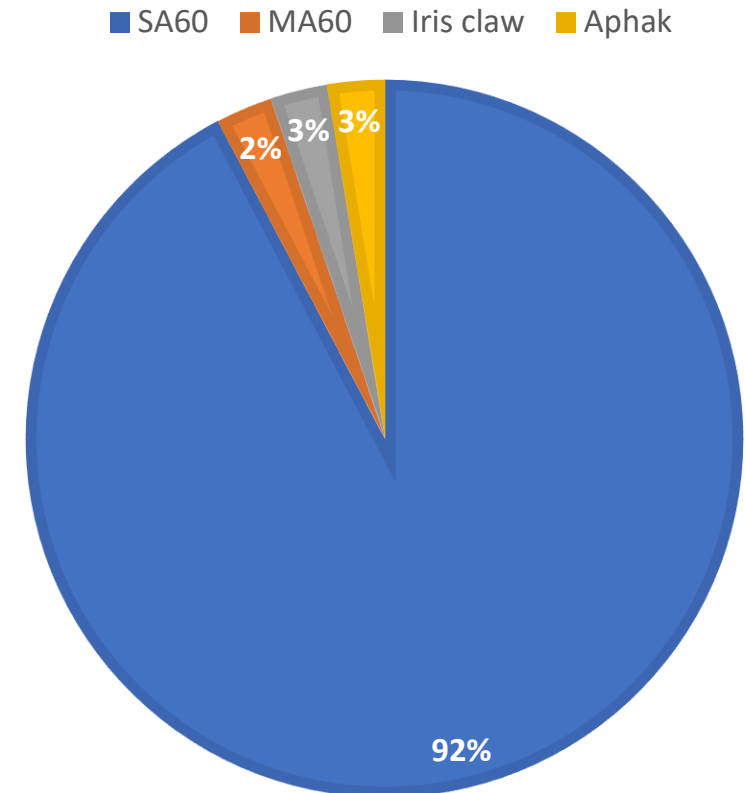
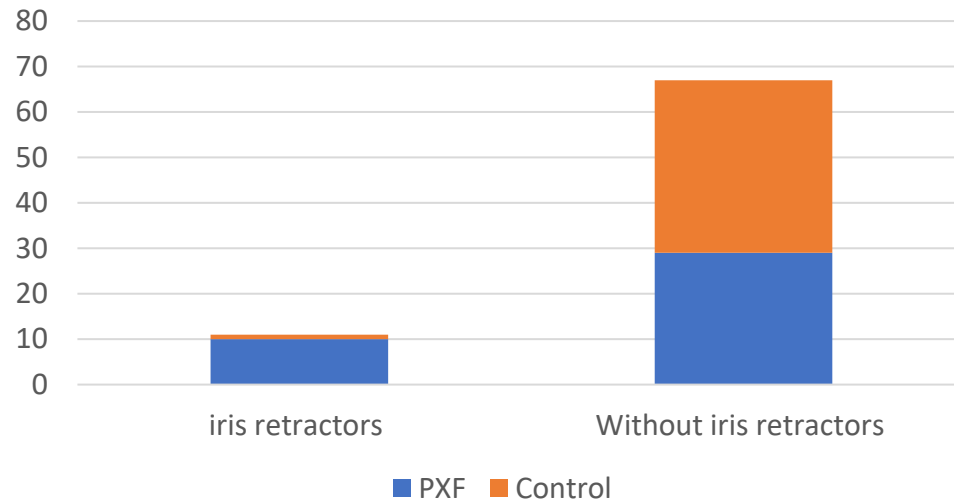
## II. Clinical data

Cataract type	PXF n(%)	Control
Nuclear	4 (10,3%)	3 (10,3%)
Cortical	1 (2,6%)	1 (2,6%)
Cortico-nuclear	11 (28,2%)	5 (12,8%)
Posterior subcapsular	2 (5,1%)	2 (5,1%)
CN + posterior subcapsular	19 (48,7%)	27 (69,2%)
Mature	2 (5,1%)	1 (2,6%)

Type of cataract and number of eyes with and without pseudoexfoliation

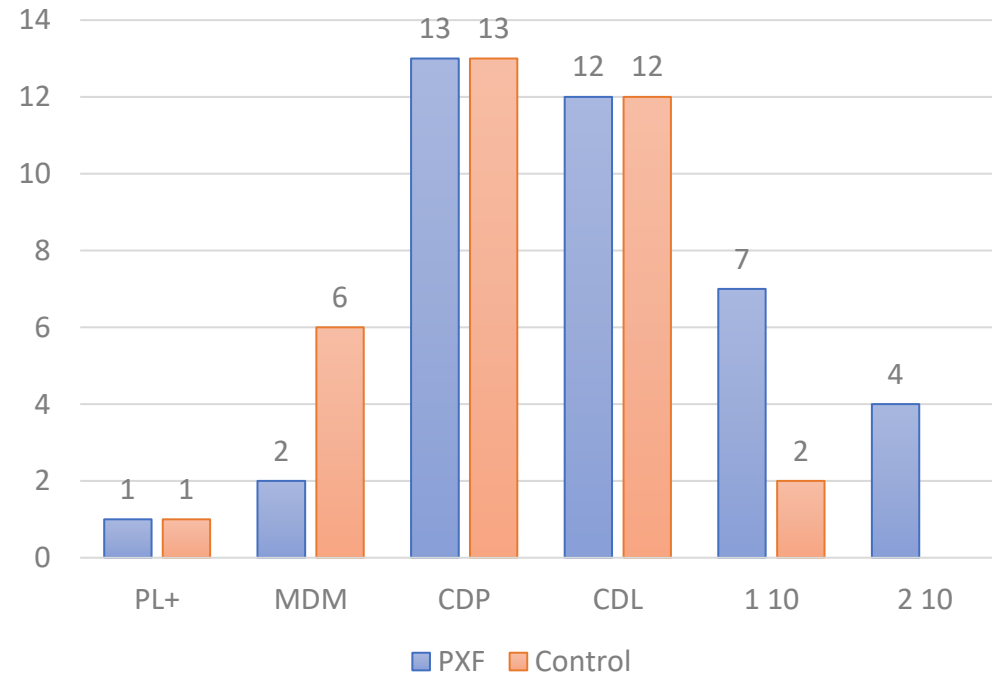


### III. Preoperative difficulties

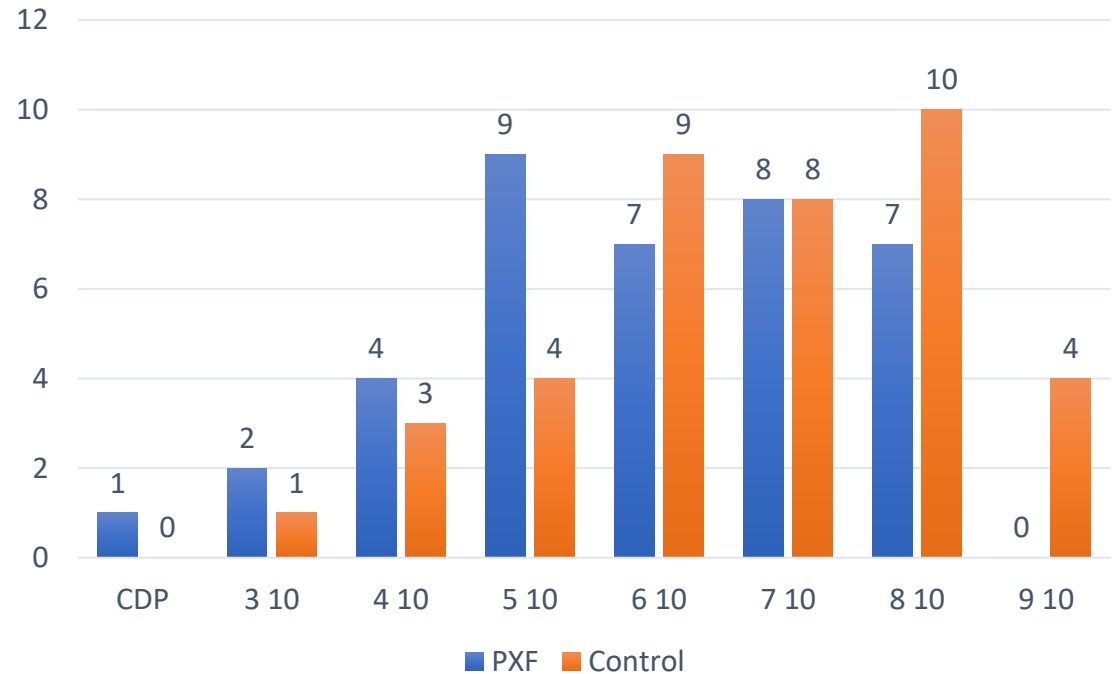


Surgical complications	PXF	Control
Rhexis extension	1 (2,5%)	2 (5,1%)
Zonular dehiscence	3 (7,6 %)	-
Posterior capsularrupture	2 ( 5,1%)	1 (2,6%)

## IV. Visual acuity evolution



Preoperative corrected visual acuity



Postoperative visual acuity

Introduction

Materials and  
Methods

Results

Discussion

Conclusion

# Discussion



Introduction

Materials and  
methods

Results

Discussion

Conclusion

Original Article

Frequency and surgical difficulties associated with pseudoexfoliation syndrome among Indian rural population scheduled for cataract surgery: Hospital-based data

- PEC syndrome is an age-related disorder
- The prevalence increases significantly 60 years of age
- In our study, the age group between 61 and 70 years, was the most affected (38,5%)
- Similar observations were noted by Al-Shaer *et al.* in Yemen, wherein 10.1% patients between 41 and 50 years old and 28.8% >81 years old had the syndrome, as well as in other studies from North Nigeria, Riyadh (Saudi Arabia), South India, Turkey, and Ethiopia.

Table 1: Age and number of eyes with pseudoexfoliation

Age (years)	Number of eyes with PXF n=226 (%)
51-60	10 (4.42)
61-70	60 (26.5)
71-80	75 (33.2)
81 and above	81 (35.8)

As the age increases eyes with PXF increases

61-70	15 (38,5%)
71-80	12 (30,8%)

## Introduction

## Materials and methods

## Results

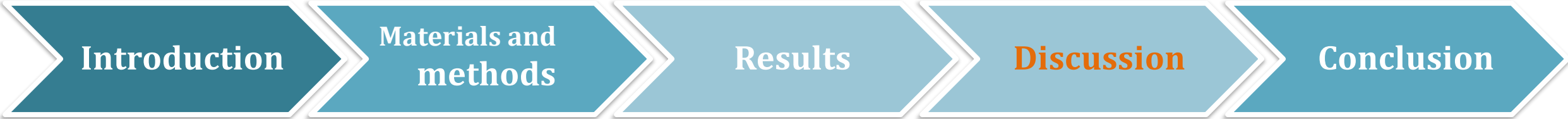## Discussion

## Conclusion

Authors	Bilaterality	Unilaterality
R.KARAMI and al (Morocco)	17 (80%)	4 (20%)
Joshi RS (India)	86 (38,1%)	70 (30,9%)
Gelaw and Tibebe	96 (66.7%)	48 (33.3%)
M. Streho and al (France)	38 %	61 %
Our study	29 (74,4%)	10 (25,6%)

in 70 eyes (31%). In the study by Gelaw and Tibebe, 48 patients (33.3%) had unilateral involvement, whereas 96 patients (66.7%) had bilateral involvement.<sup>[38]</sup> Most studies have reported bilateral involvement more than unilateral involvement, as the unilateral disease is expected to progress to bilateral condition.<sup>[20,32,33,37]</sup> Another possible explanation

térale ( 20%). Selon l'étude de Puska et al. [11], il s'agit d'une atteinte bilatérale, mais de présentation asymétrique avec un long délai entre les deux yeux : 38 % de bi latéralisation à 10 ans. Dans les formes unilatérales, l'œil avec une



Authors	Poor dilatation	Iris retractors
R.KARAMI and al (Morocco)	5 (23%)	1 (4,75%)
Joshi RS (India)	32 (14.2%)	12 (5,3%) at the begining 5 (2,2%) during nucleus aspiration
Philip <i>and al</i>	96.7%	-
M. Streho and al (France)	-	2 (5,4 %)
Our study	12 (30,8%)	10 (25,6%)

## Le syndrome de pseudo-exfoliation capsulaire dans la chirurgie de la cataracte. Étude rétrospective de 37 cas

M. Strehö, C. Rohart, B. Guigui, F. Fajnkuchen, G. Chaine

cataracte observés dans le groupe PEC était : cortico-nucléaire (40 %), blanche (24 %), sous-capsulaire (20 %) et nucléaire (16 %). Pour le groupe témoin, la

CN + posterior subcapsular 19 (48,7%)

**Table 4: Type of cataract and number of eyes with pseudoexfoliation**

Type of cataract	Number of eyes with PXF (%)
Hypermaturation	98 (43.4)
Mature	50 (22.1)
Nuclear	26 (11.5)
Cortical	25 (11.1)
Posterior subcapsular	20 (8.9)
Posterior polar	07 (3.1)
Total	226

Hypermaturation cataract was common

**Introduction****Materials and methods****Results****Discussion****Conclusion**

Authors	Surgical complications (PXF group)	Surgical complications (Control group)
R.KARAMI and al (Morocco)	15%	1%
Hyams and al	5,8%	4%
Joshi RS (India)	27.4%	-
Naik and Gadewar	26%	-
M. Streho and al (France)	5,4 %	5,4 %
Our study	15,2 %	7,7%

**Table 5: Surgical difficulties in eyes with pseudoexfoliation**

Surgical difficulties	Number of eyes (%)
Poor pupillary dilatation	32 (14.2)
Pupillary catch	01 (0.4)
Rhexis extension	02 (0.9)
Zonular dehiscence	18 (8)
Posterior capsular rupture	03 (1.3)
Conversion to small incision cataract surgery	05 (2.2)
Total	62 (27.4)

Poor pupillary dilatation was common problem followed by zonular dehiscence

However, Shastri and Vasavada have reported that intraoperative performance of cataract surgery in PXF eyes is comparable to that in non-PXF eyes.<sup>[30]</sup> In our study, intraoperative



**Introduction**


**Materials  
and methods**

**Results**

**Discussion**

**Conclusion**

# **Conclusion**

- Pseudoexfoliation syndrom is a common condition among patients scheduled for cataract surgery.
- Pseudoexfoliation syndrom            Age and small pupils
- Zonular weakness and small pupils were common intraoperative difficulties.
- Capsular tension ring and iris retractors !!!