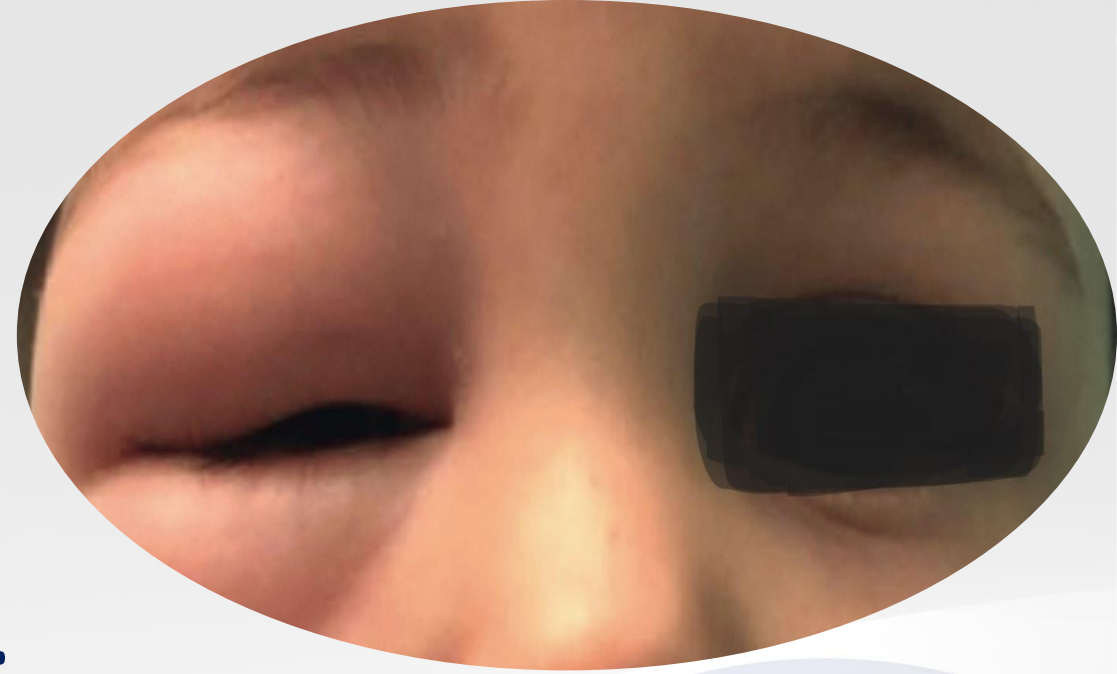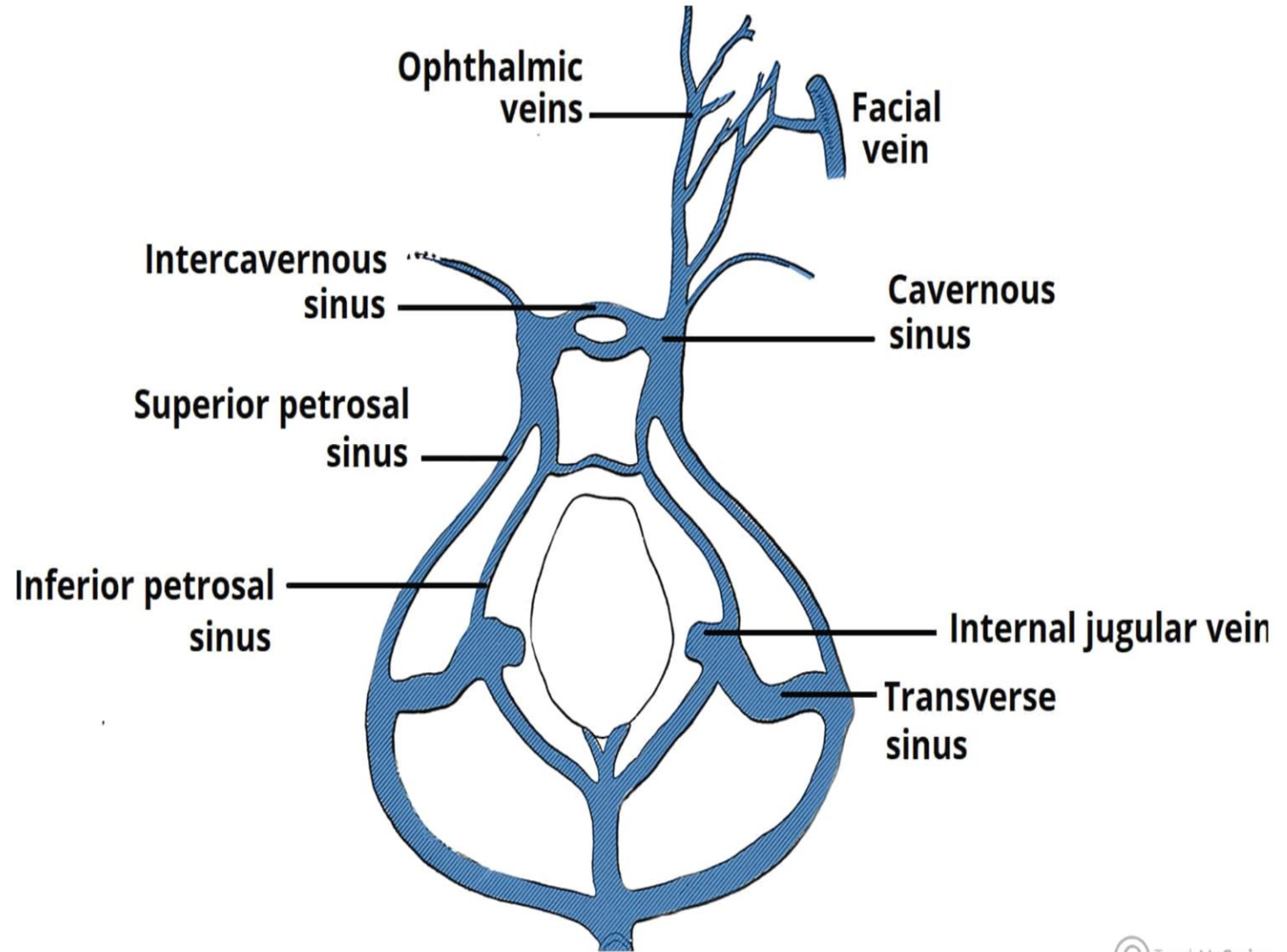
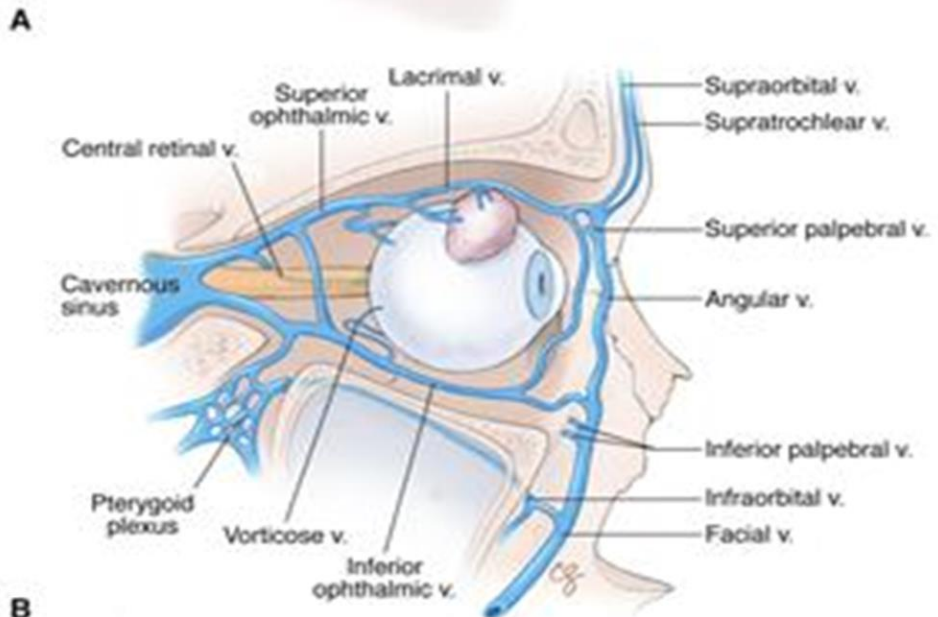
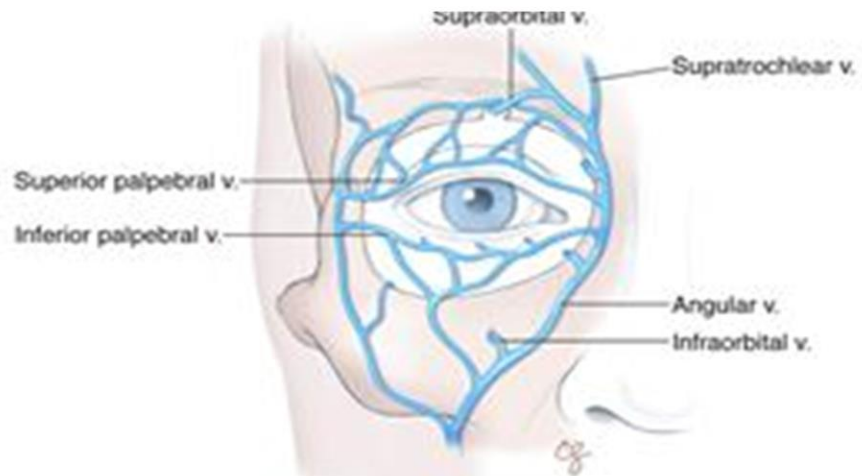


Superior ophthalmic vein thrombosis – Case report

Ahmed Elsaadawy
GP ST1



Anatomy



Our patient

Age: <10 years.

Gender: Male

Allergies: None

Ethnicity: Caucasian



PMH Previously treated **Exotropia**.
ADHD.

NO diabetes mellitus, family history of vascular or blood diseases, etc...

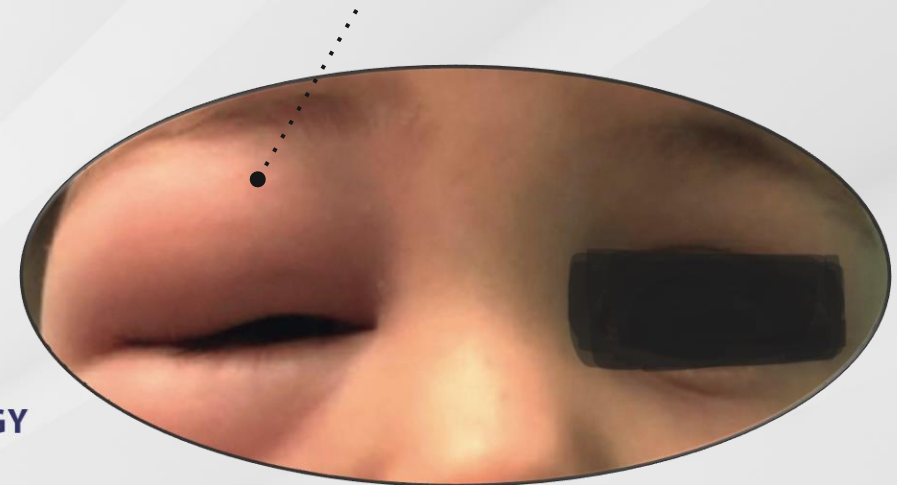
Presentation to A&E

- Low grade fever & Headache.
- **URTI** symptoms (runny nose, tiredness).
- Minor **injury** to the face near the eyelids → This was considered as cause for the **minimal eyelids swelling**.
- Discharged with safety netting advice.

Next day:

- Persisting above symptoms, with:
- Worsening eyelids swelling & tenderness in medial canthus.
- No visual impairment or neurology detected.

Eyelids inflammation & swelling.



Diagnosis

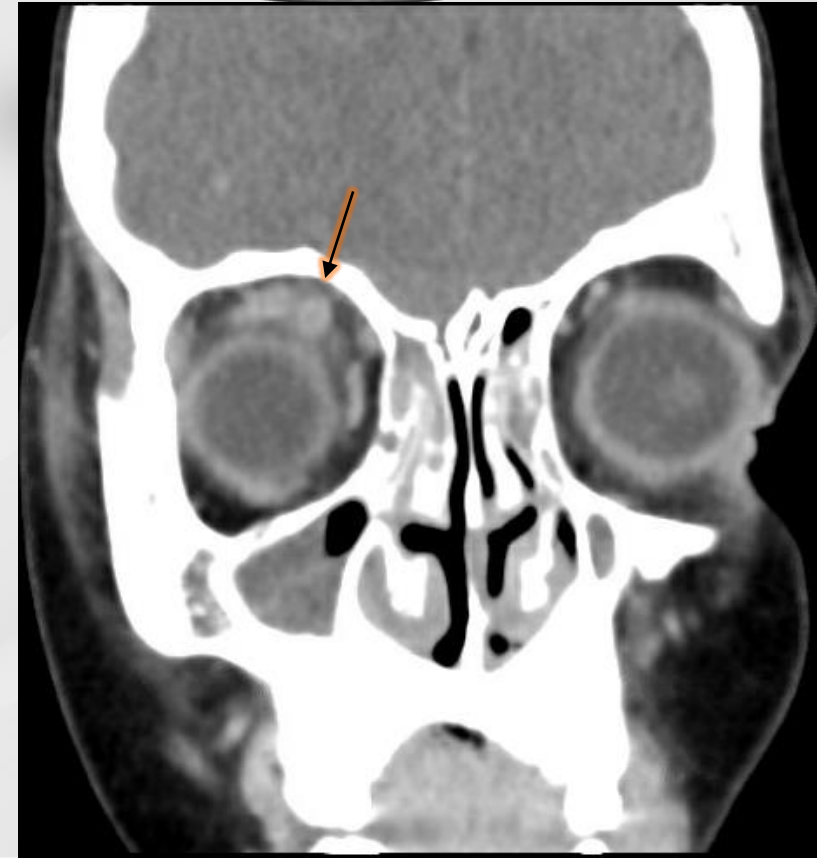
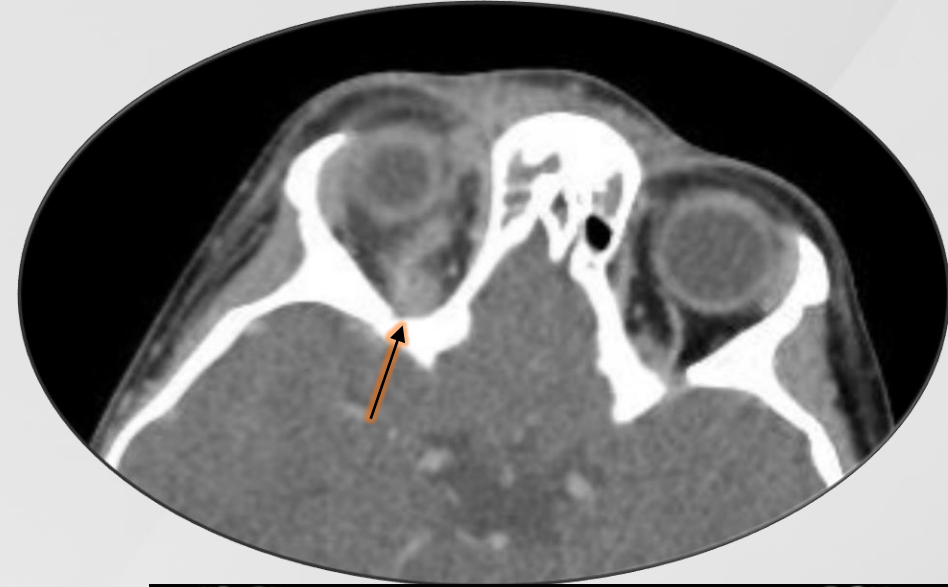
Despite admission and **IV antibiotics**, **No improvement was observed.**

The patient started developing:

- Worsening of his symptoms (lid swelling & pain)
- **Painful, limited right eye elevation.**

Contrast CT orbits, sinuses & brain, revealed:

- SOVT
- Pansinusitis.



Management

- 1) MDT (Ophthalmologists, Paediatrician, Paediatric haematologist & Microbiologist).
- 2) **Antibiotics**: A phase of IV Co-amoxiclav for ?pre-septal cellulitis Mx, later switched to IV Ceftriaxone & Metronidazole.
- 3) **Low Molecular Weight Heparin (Dalteparin)**, was initiated following CT confirmation of SOVT.
(Duration: 3 months)
- 4) Repeat **CT scans** to monitor SOV patency. (within few days, repeated after 1-2 months).
- 5) Significant improvement of symptoms only within 1-2 days of anticoagulation.
- 6) Regular follow up with Ophthalmology consultant.

Take away points

- High level of clinical suspicion, in **all** age groups.
- Awareness to clues in ophthalmic examination (slow venous circulation vs. cellulitis).
- MDT management is crucial in optimising treatment.



Thank you..

Questions?



References

Example Face picture (Internet, edited for more anonymity):

Ento key website

- <https://entokey.com/preseptal-and-orbital-cellulitis-2/>

