



Lens ectopia in children:

Experience of the pediatric ophthalmology service in Casablanca

L.Ajdour ; A.Elharrar; R.Chahir ; H.Jdid ; G. Daghouj ; L. El Maaloum ; B. Allali ; A. El Kettani

Pediatric ophthalmology department

Chu Ibn Rochd , Casablanca

EPOMECE 2023

Introduction

Material and methods

results

Discussion

Conclusion

- Lens ectopia: congenital displacement of the lens due to an abnormality of the zonule.
- Rare disease
- Serious and progressive : - visual prognosis
- vital prognosis
- Isolated or as a part of a syndrome
- Problem of its etiology and management : optical and rehabilitative

Introduction

**Material and
methods**

Results

Discussion

Conclusion

- The purpose of our work :
 - Describe the main clinical, epidemiological and progressive characteristics of this pathology.
 - Analyze the anatomical and fonctionnal results of our treatment.

Introduction

**Patients and
méthods**

Résults

Discussion

Conclusion

- descriptive retrospective study
- 70 children operated on (126 eyes)
- Pediatric ophthalmology department (Casablanca)
- 13 years (January 2010 - august 2023)

Introduction

**Patients and
methods**

Résultats

Discussion

Conclusion

- We studied :
 - Epidemiological elements
 - Ophthalmological examination
 - Etiology
 - Medical and surgical treatment
 - Evolution
- Excluded: subluxations of the lens of traumatic origin

Introduction

Patients and
méthods

Résultats

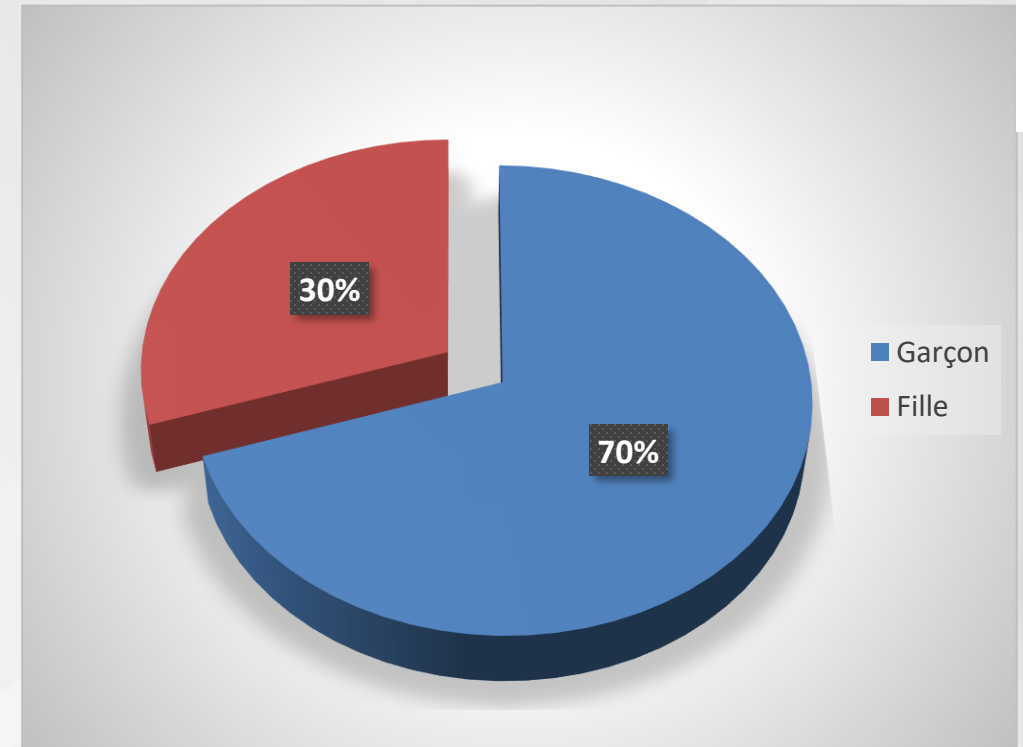
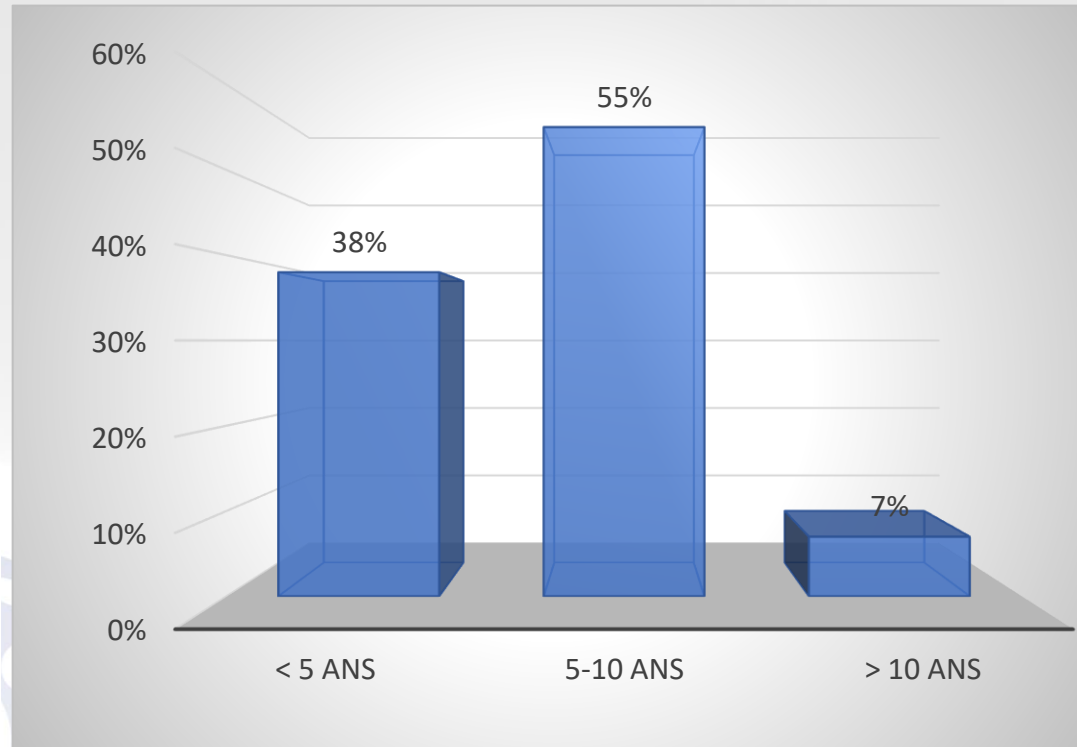
Discussion

Conclusion

✓ Age

✓ Average age 7,5 ans

✓ gender



Introduction

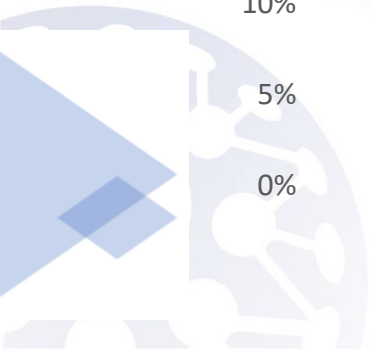
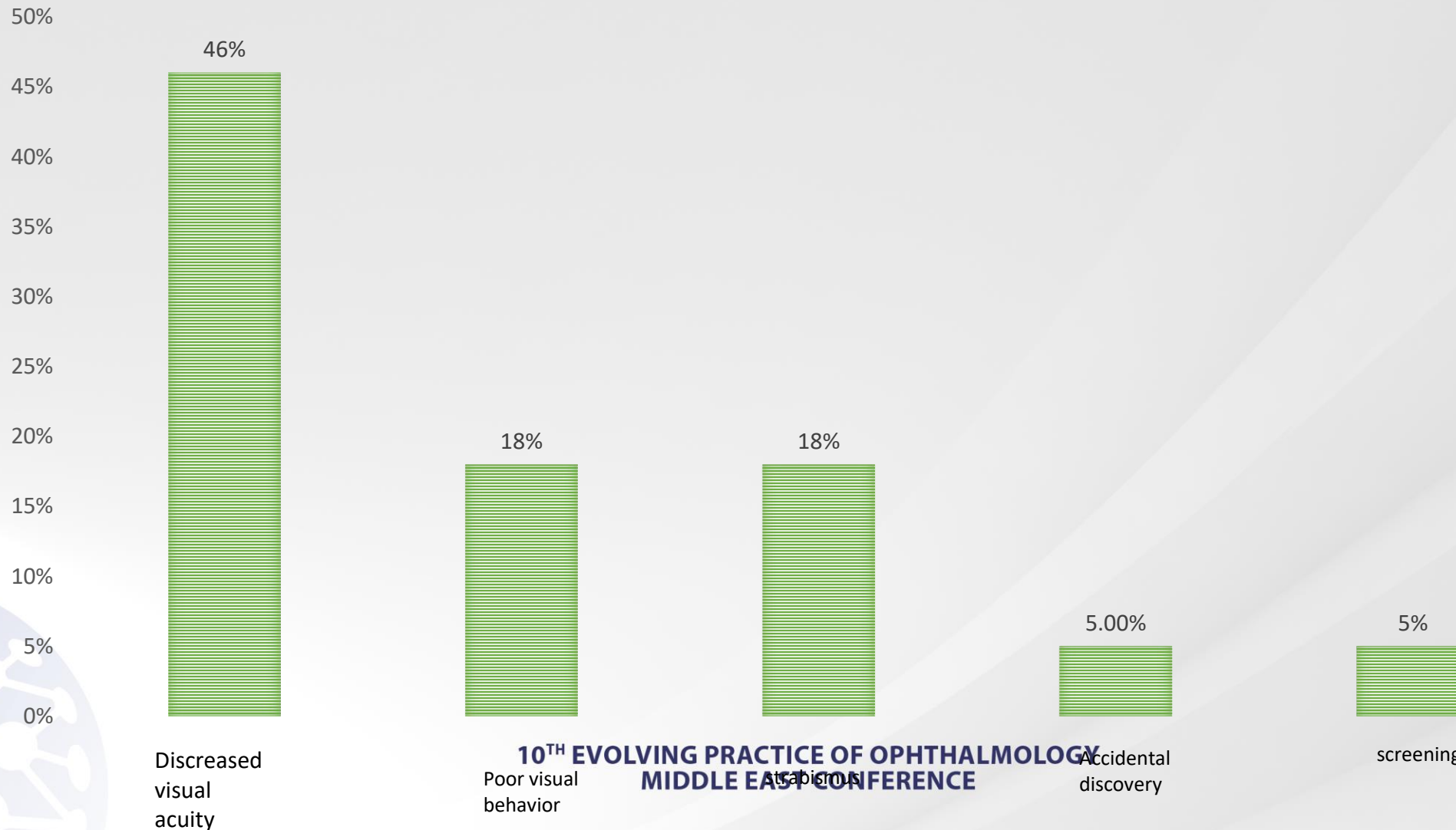
Patients and methods

Résults

Discussion

Conclusion

✓ reason for consultation:



Introduction

Patients and
methods

Results

Discussion

Conclusion

✓ **Personnal and family history :**

- Concept of consanguinity : 22 cases (**36 %**)
- similar cases in the family : 10 cases (**16 %**)
- Delay in psychomotor development : 5 cases (**12%**)

Introduction

Patients and
methods

Results

Discussion

Conclusion

- ✓ **Visual acuity on admission:** between hand movement and 3/10 in all patients
- ✓ **Refraction under cycloplegia :**
 - Astigmatism always found : (-3,75D)
 - medium myopia -13 D (-2 et over sphère)
- ✓ **Bilateral form in 100% of cases :**

Introduction

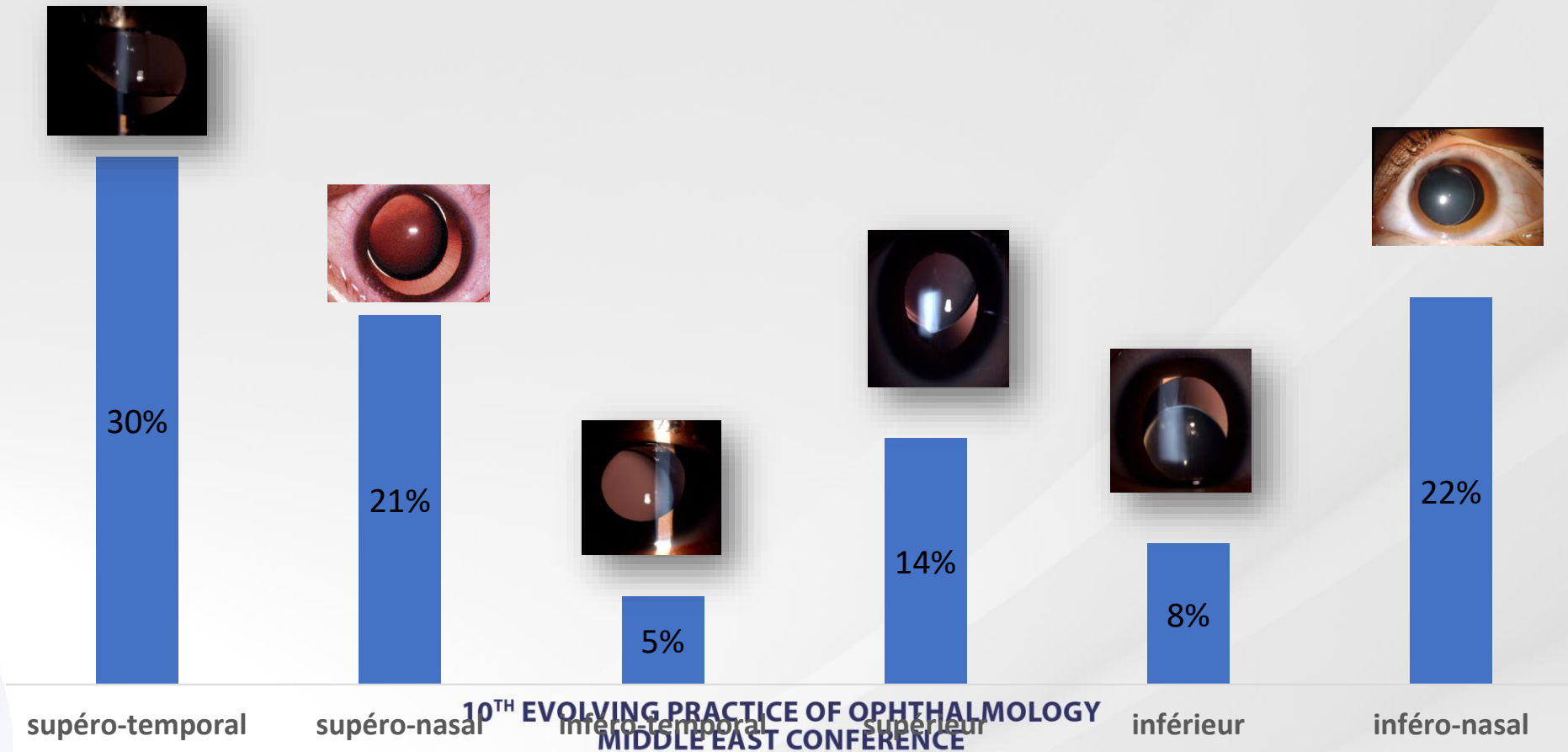
Patients and
methods

Results

Discussion

Conclusion

✓ Type of lens ectopia :



Introduction

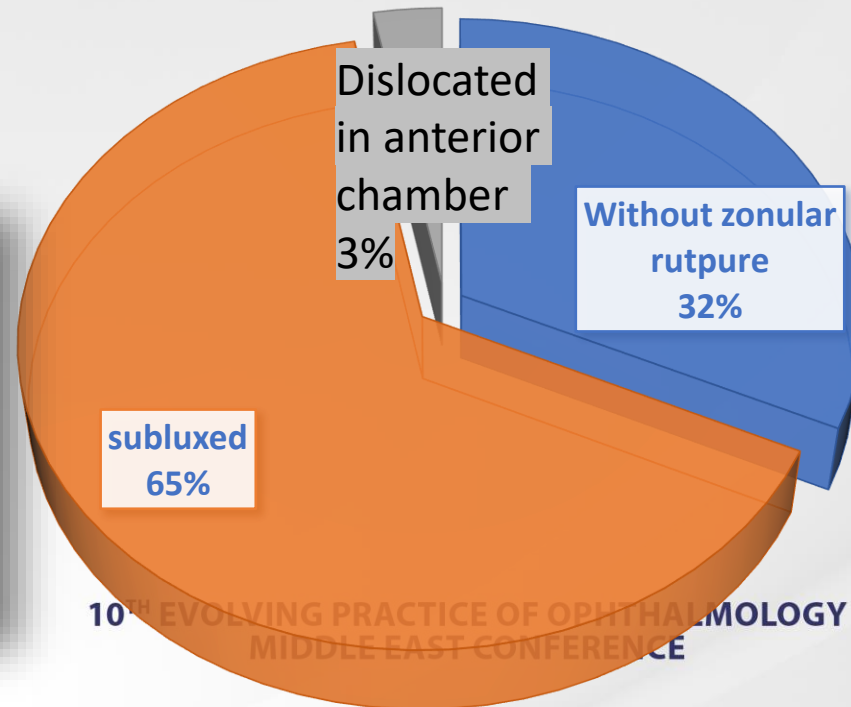
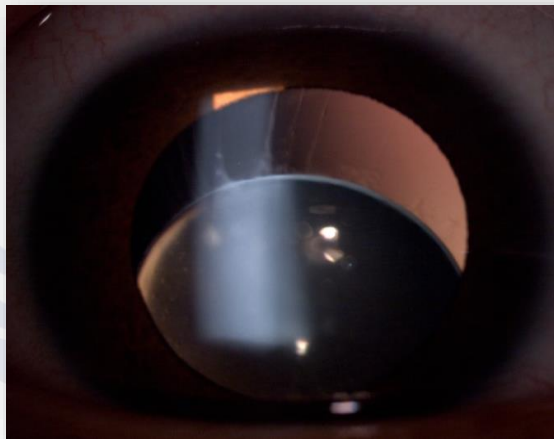
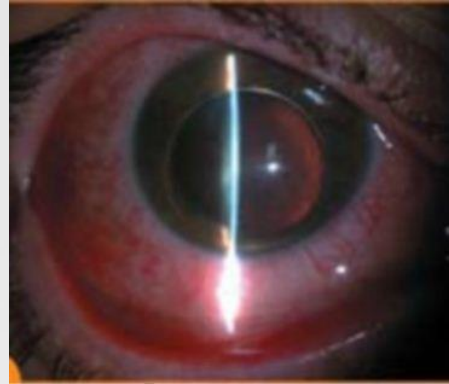Patients and
methods

Résults

Discussion

Conclusion

✓ Clinical anatomical type :



Introduction

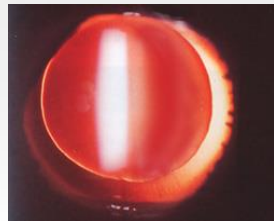
Matériel and methods

Résults

Discussion

Conclusion

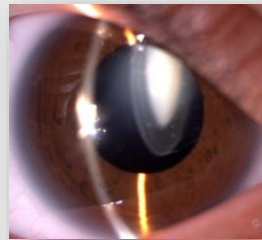
✓ Other associated anomalies :



5%



aniridia



14%



cataract

11%




Chorio-retinal atrophy

20%




Degenerative retinal lesion

2%



Retinal detachment

2.50%



Ocular hypertonia

Introduction

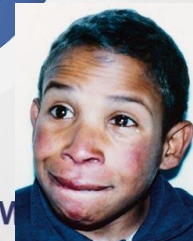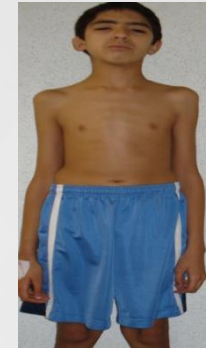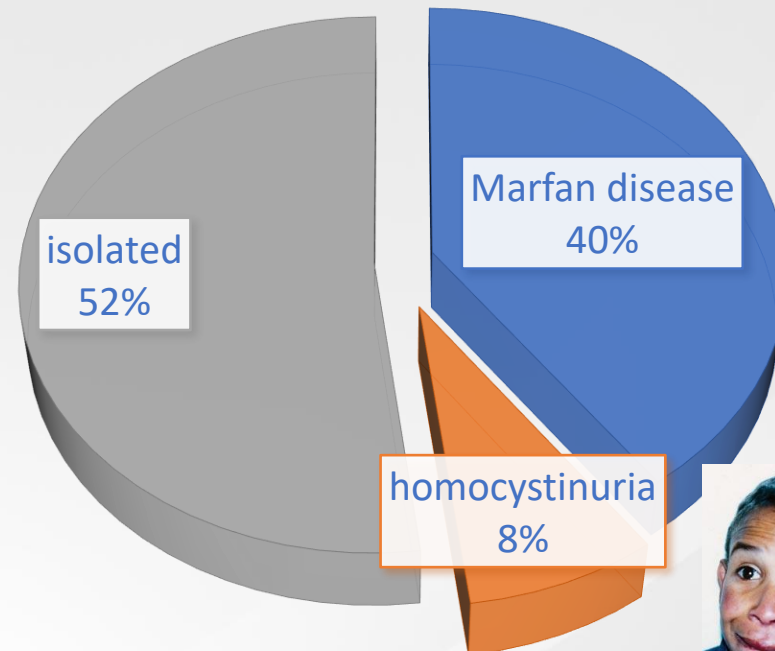
Matériel and
methods

Résults

Discussion

Conclusion

✓ Etiologies:



10TH EVOLVING PRACTICE OF OPHTHALM
MIDDLE EAST CONFERENCE

Introduction

Matériel and
méthods

Résults

Discussion

Conclusion

- ✓ **Heart disease : 5 patients**
 - **Mitral insufficiency**
 - **aortic dilatation**

Introduction

Patients and
méthods

Résults

Discussion

Conclusion

✓ **Treatment**

Surgical treatment	Eyes number	Percentage
Phacophagy and capsular bag removal + anterior vitrectomy	124	98.4%
ICE + AV + Artisan	2	1.6%

Introduction

Patients and
methods

Résults

Discussion

Conclusion

➤ Visual rehabilitation is based on :

→ aphakia glasses and lenses

→ **Amblyopia treatment** +++

Introduction

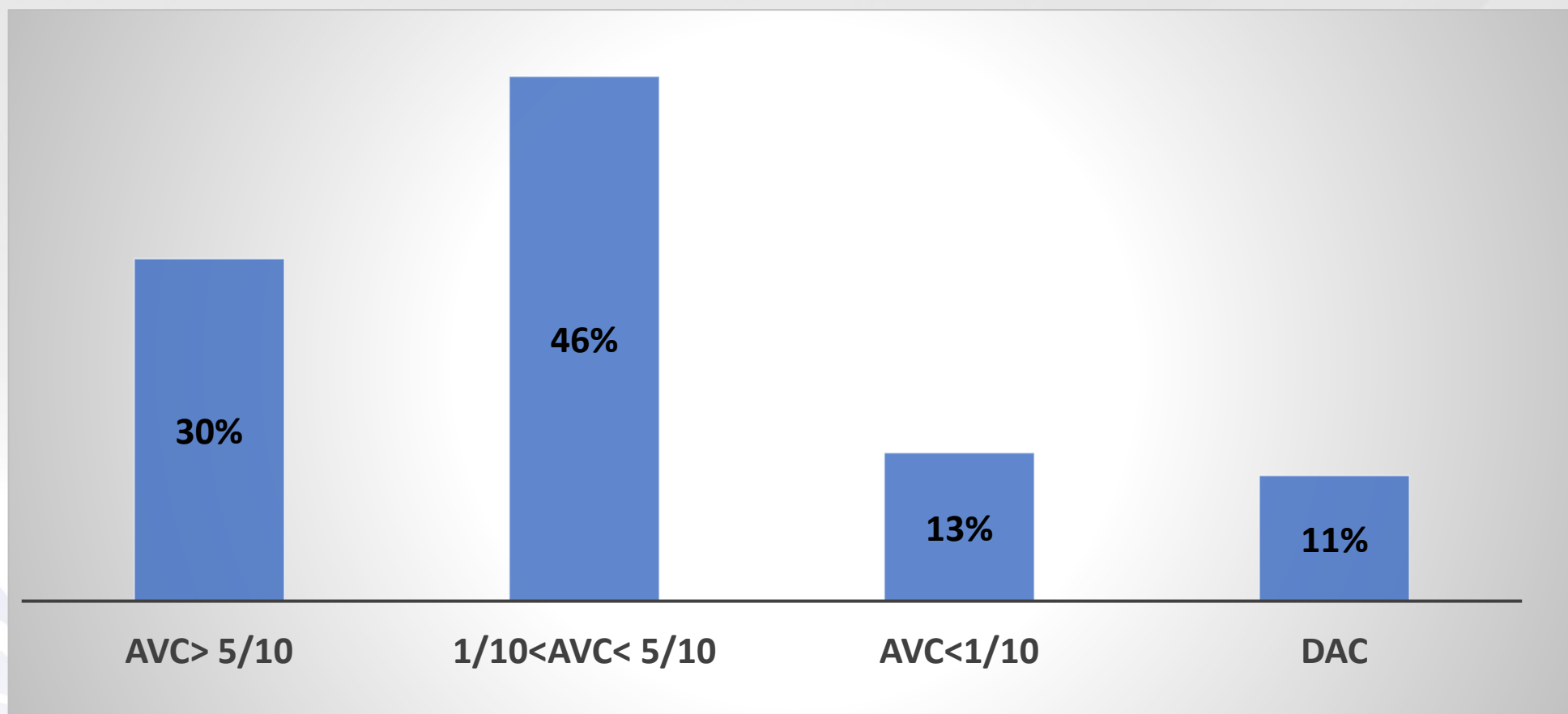
Patients and
methods

Résults

Discussion

Conclusion

✓ **Final visual acuity**



Introduction

Patients and
methods

Résultats

Discussion

Conclusion

✓ **Les complications post-opératoires :**

Post operatives complications	Eyes number	Percentage
Retinal detachment	2	1,5%
Inflammatory reaction	3	2%
Chronic glaucoma	2	1,5%

Introduction

Patients and
methods

Résultats

Discussion

Conclusion

- Lens ectopia: congenital displacement of the lens due to an abnormality of the zonule.
- Rare with prevalence of 0,2 /10 000 births
- Progressive and provider of serious complications
- Represents 0,3% of congenital ocular anomalies
- Often bilateral involvement +++

Introduction

Patients and
methods

Résultats

Discussion

Conclusion

	Wen Y. Wu- Chen (USA)	Sorath. N (Pakistan)	Nejjari.O (Fès)	Notre série (Casablanca)
Age of diagnosis : years (patients number)	7,7 (11)	9,4 (50)	16 ans (18)	7,5 ans (63)
Male gender	52%	60%	68%	70%
Direction of lens ectopia	Inferior (29,4%)	Temporal (36,5%)	inferotemporale (41%)	Supéro-temporal (30%)
Bilateral involvement	100%	100%	100%	100%
Initial visual acuity	CLD à 2/10	CLD à 2/10	MDM à 1/10	MDM à 3/10
Ocular hypertonia	6%	13%	4%	2,5%

1- Sorath N, Khan A, Shehla R and al. Management of Ectopia Lentis in Children. Pak J Ophthalmol, 2007 ; 23, 4 : 181-187.

2- Wen Y Wu-Chen, Letson RD, Summers CG. Functional and Structural Outcomes Following Lensectomy for Ectopia Lentis. Journal Of American Association For Pediatric Ophthalmology And Strabismus, 2005 ; 9 : 353-357.

Introduction

Patients and
methods

Résults

Discussion

Conclusion

	Wen Y. Wu-Chen (USA) %	Sorath. N (Pakistan) %	J. Fuchs (Danemark) %	Notre série (Casablanca) %
Marfan disease	52,9	22	47,2	40%
Weill Marchesani disease	0	4	0,5	0
Homocysteinury	11,7	2	0,75	8%
d'Ehrles Danlos disease	0	0	0	0
Simple lens ectopia	11,7	72	5,55	52%
Pupillary ectopia	17,6	0	14,64	0
sulfite oxydase deficiency	0	0	0,5	0

1- Sorath N, Khan A, Shehla R and al. Management of Ectopia Lentis in Children. Pak. J. Ophthalmol, 2007 ; 23, 4 : 181-187.

2- Wen Y Wu-Chen, Letson RD, Summers CG. Functional and Structural Outcomes Following Lensectomy for Ectopia Lentis. Journal Of American Association For Pediatric Ophthalmology And Strabismus. 2005 ; 9 : 353-357.

Introduction

Matériel et
méthodes

Résultats

Discussion

Conclusion

- Ectopia lens can cause significant reduction of visual acuity :
 - Degree of ectopia
 - Associated ocular damages
 - Age of onset of disease
 - General illness
- Conservative treatment / surgical treatment

1- Sorath N, Khan A, Shehla R and al. Management of Ectopia Lentis in Children. Pak. J. Ophthalmol, 2007 ; 23, 4 : 181-187.

2- Wen Y Wu-Chen, Letson RD, Summers CG. Functional and Structural Outcomes Following Lensectomy for Ectopia Lentis. Journal Of American Association For Pediatric Ophthalmology And Strabismus, 2005 ; 9 : 353-357.

3- Konradsen T, Kugelberg M, Zetterström C. Visual outcomes and complications in surgery for ectopia lentis in children. J Cataract Refract Surg, 2007 ; 33 : 819-824.

4- Rahman A, Bhutto IA, Bukhari S. Visual Outcome and Complications in Ab-Externo Scleral Fixation IOL in Aphakia. Pak J Ophthalmol, 2011 ; 27

Introduction

Matériel et
méthodes

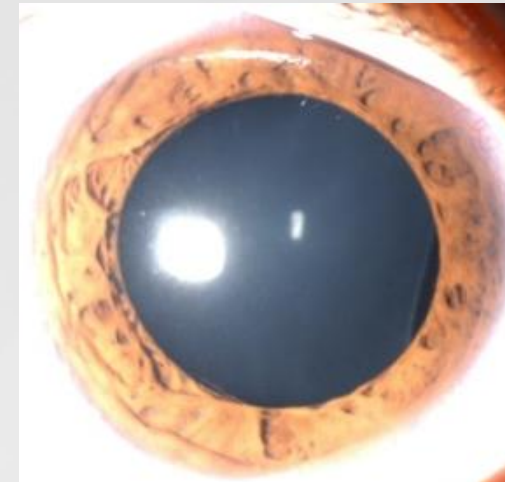
Résultats

Discussion

Conclusion

- **Conservative treatment:**

- Absence of significant refractive disorders
- Uncomplicated lens ectopia
- Close surveillance



Optical correction of
myopia and
astigmatism

Introduction

Patients and
methods

Résultats

Discussion

Conclusion

- **surgical treatment:**

- Challenge
- Visual acuity < 3/10, important displacement, complications (lens dislocation, ocular hypertonia, diplopia)
- Several surgical technics +++ :
 - Etiology
 - Clinical form
 - Evolutionary stage

Phacophagia
+
Anterior vitrectomy

Introduction

Patients and
methods

Résultats

Discussion

Conclusion

	T. Konradsen	A. Rahman	N. Sorath	Wen Y. Wu-Chen	Notre série Casablanca
Years	2007	2011	2007	2005	2022
Eyes number	37	30	96	17	126
Phacophagia, anterior vitrectomy	-	-	100%	100%	98,4%
Phaco, ATC Cionni et IOL sutured to the sclera	100%	100%	-	-	-
ICE + AV+artisan	-	-	-	-	1,6%
Success rate : VA\geq3/10	94,6%	96%	71%	82,4%	70%

The discovery of a case requires an etiological investigation and family screening with regular monitoring even after

Introduction

Patients and
methods

Résults

Discussion

Conclusion

- Ectopic lens: serious illness == significant organic and functional complications
- Diagnostic and therapeutic emergency
- Conservative treatment is reserved for minor uncomplicated forms with close monitoring, otherwise it's surgical
- One of priorities of care is to search for and treat an associated general illness
- The discovery of a case requires an etiological investigation and family screening with regular monitoring even after surgical treatment.

Merci pour votre attention

Références

- **Molecular pathogenesis and management strategies of ectopia lentis**
A-Chandra and D-Charteris
- **Functional and structural outcomes following lensectomy for ectopia lentis**
When Y Wu-Chen, Robert D Letson, C Gail Summers
- **Management of ectopia lentis in children**
D-E-Neely, D-A-Plager
- **Pathologie du cristallin chez l'enfant : Rapport SFO 2017**

