

Overcome the shortage, try to be creative

Dr.Assem Anwar

Al Matarya Teaching Hospital

Connect eye Academy

Female, 20 Years-old Patient,
Seeking for Refractive Surgery
as she was unsatisfied with
her optical correction.



□ History :

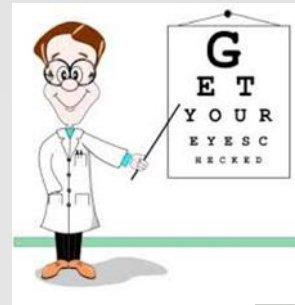- Irrelevant medical and surgical history.
- Family history of **Marfan syndrome**



□ General Examination

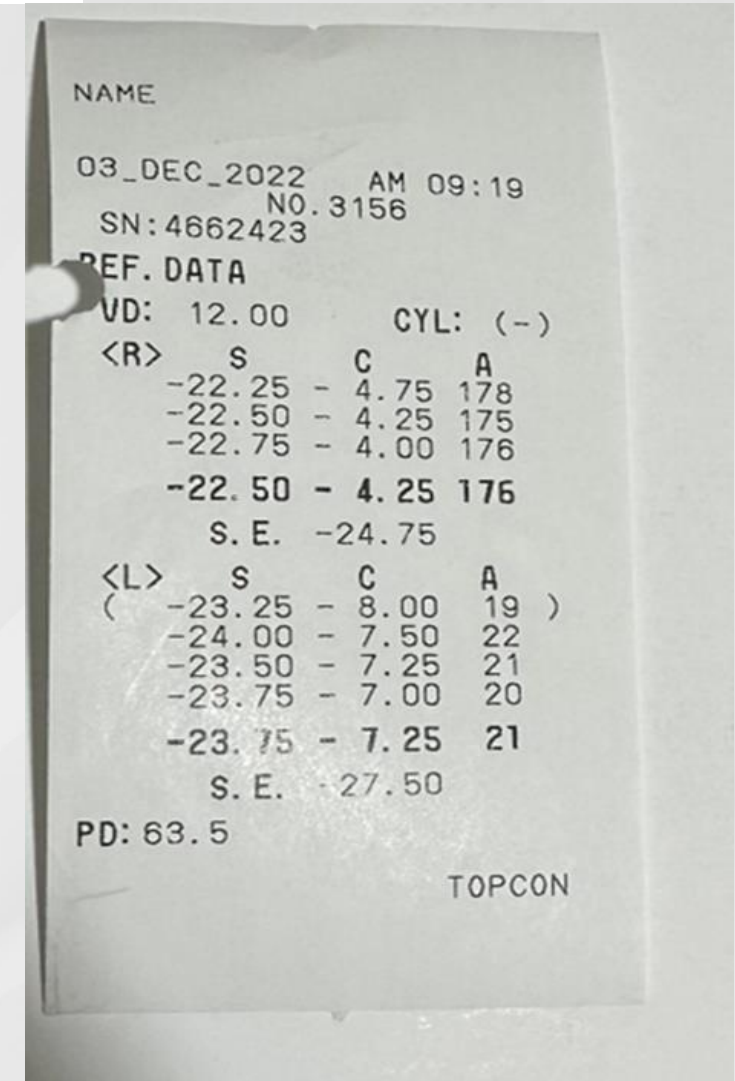
- she was tall and thin with increased arm span and showed Hypermobility of her Joints.

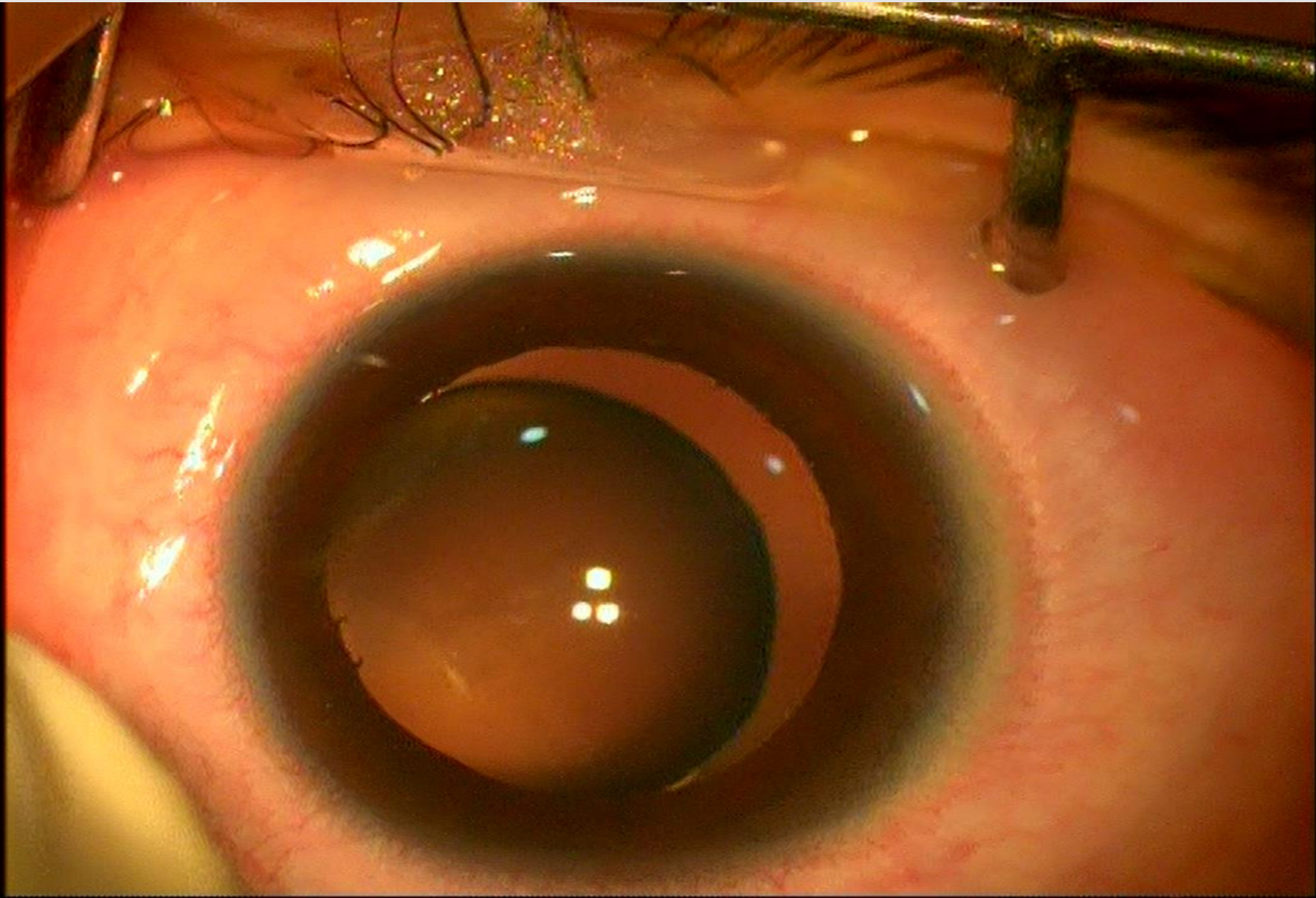




Ocular Examination:

	Right Eye	left Eye
BCVA	0.2	0.2
Cornea	Clear	Clear
Lens	Clear	Clear
	Ectopia lentis (Zonular dehiscence > 180°)	
Fundus	Tigroid Fundus	
IOP	14	13






**10TH EVOLVING PRACTICE OF OPHTHALMOLOGY
MIDDLE EAST CONFERENCE**

□ Our patient :

- Marfan syndrome.
- Bil. ectopia lentis.
- High myopia and astigmatism.





**10TH EVOLVING PRACTICE OF OPHTHALMOLOGY
MIDDLE EAST CONFERENCE**



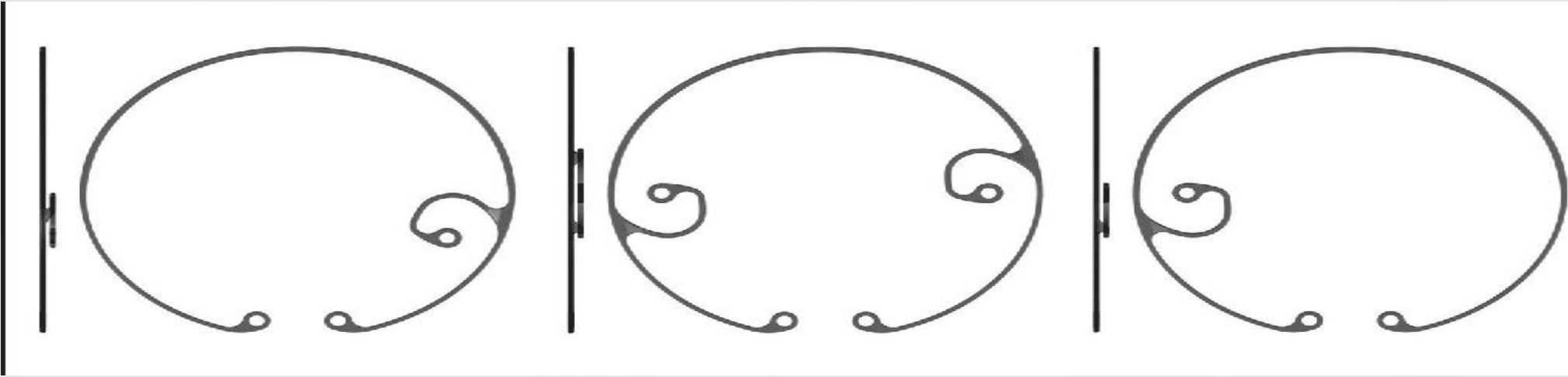
Treatment options

ICCA with correction of aphakia:

- Glasses or contact lens
- Iol implantation:
 - ACIOL
 - Iris fixated iol
 - Scleral fixated iol

Clear lens extraction with iol implantation:

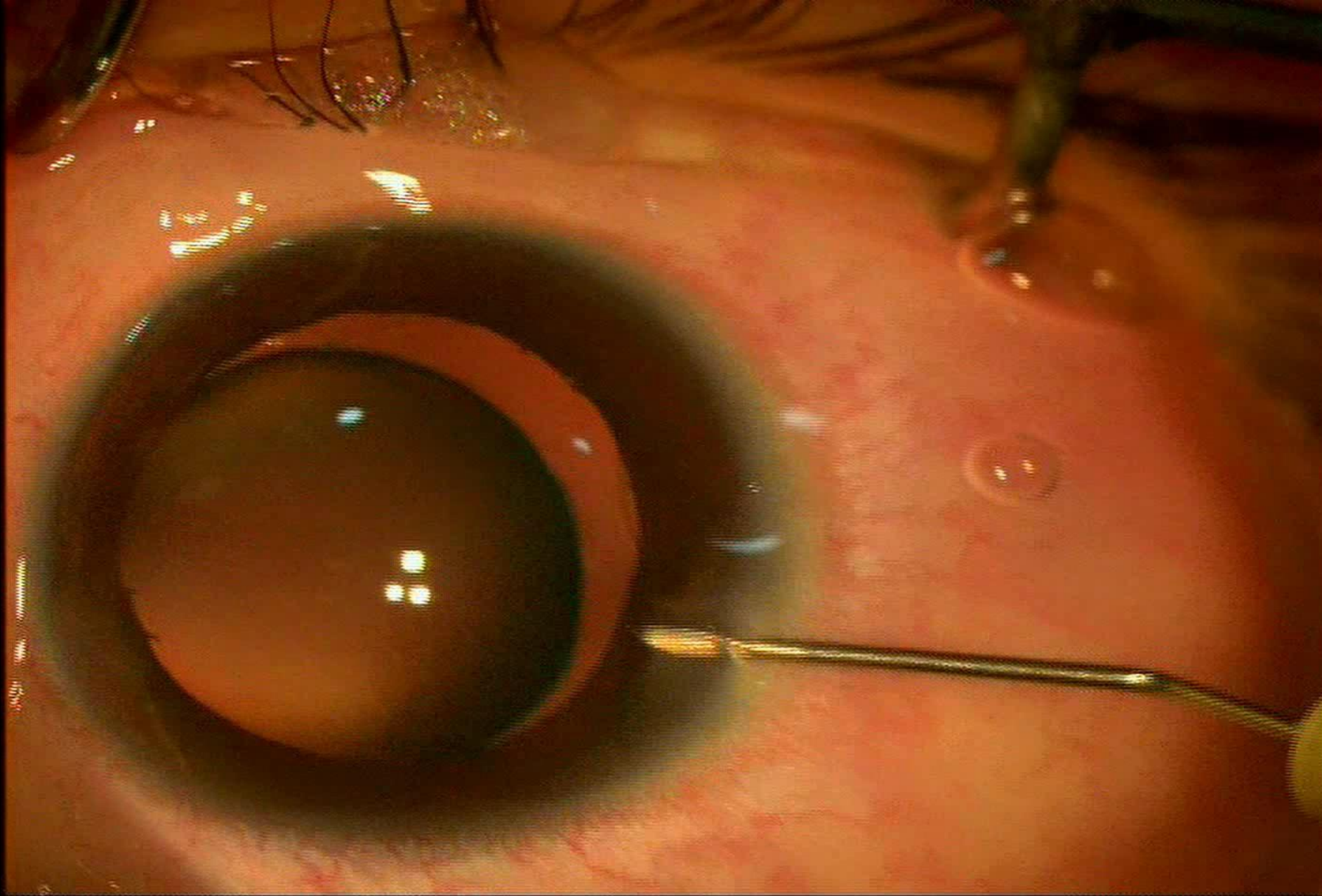
- Foldable iol in the capsular bag
- Scleral fixation of the bag



**10TH EVOLVING PRACTICE OF OPHTHALMOLOGY
MIDDLE EAST CONFERENCE**



10TH EVOLVING PRACTICE OF OPHTHALMOLOGY
MIDDLE EAST CONFERENCE

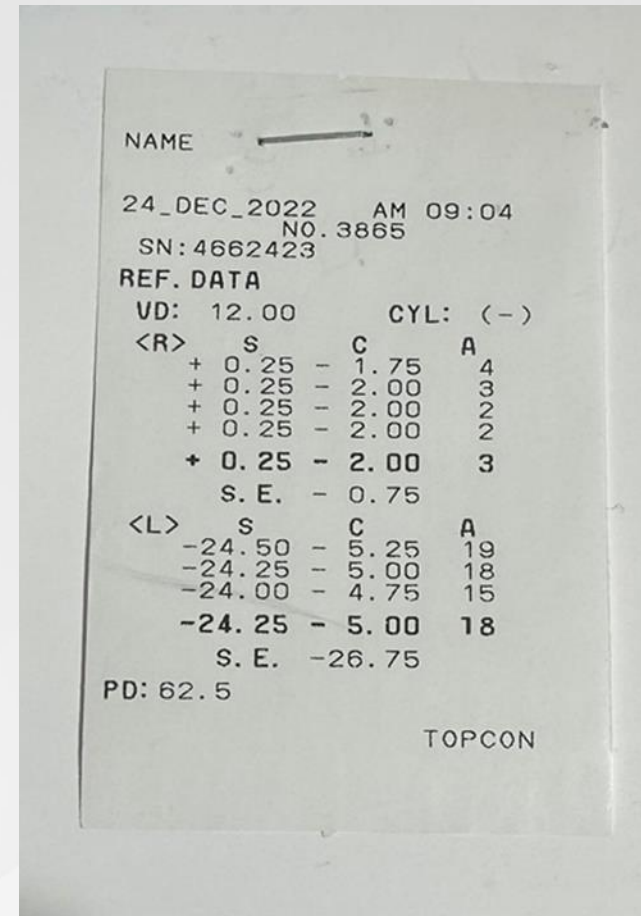


**10TH EVOLVING PRACTICE OF OPHTHALMOLOGY
MIDDLE EAST CONFERENCE**

Post-Operative Examination:



	Right Eye
BCVA	1.0
Cornea	Clear
Lens	Well Centered IOI



Conclusion

- Marfan syndrome is a common cause of ectopia lentis.
- Capsular bag fixation to the sclera shows good surgical results with less complications in cases of large Zonular dehiscence .
- Always try to be creative.





THANK
YOU

10TH EVOLVING PRACTICE OF OPHTHALMOLOGY
MIDDLE EAST CONFERENCE